

Role of Intraoperative Endoscopy during Laparoscopic Antireflux Procedure in Children

Ibrahim.A.Fakhredeen, Hazem.M.Sobeih, Mohamed.M.Elbarbary, Ehab.M.Oraby and Sherif A.Elghazzar
General Surgery Dept., Faculty of Medicine, Benha University
E-Mail:

Abstract

Purpose: To assess role of intraoperative endoscopy in antireflux procedure regard to detection of gastroesophageal junction and assessment of tightness of wrap. **Background:** Due to immaturity of the lower esophageal sphincter, which results in the retrograde passage of stomach contents into the oesophagus, gastroesophageal reflux disease is the most prevalent gastroenterologic problem requiring referral to a paediatric gastroenterologist during infancy. **Patients and methods:** This prospective study included 30 patient of pediatric Age less than 18 years old with GERD resistant to conservative treatment. This study was performed at Benha university hospital and Cairo University Specialized Pediatric Hospital at period from October, 2020 till October, 2022. The procedure was authorised by the medical school's ethics committee. Written informed permission was acquired from the parents of all patients; all patients after informed consent were subjected to laparoscopic Nissen fundoplication. During treatment procedure, endoscopy had been used to locate gastroesophageal junction (GEJ) and to assess tightness of performed valve. **Results:** there is significant decrease in early post-operative complication rate as early dysphagia 23.3%, early vomiting 10%, no cases of post-operative bleeding or post-operative pneumothorax or esophageal perforation, operative time was seen to be substantially longer in our procedure, the incidence of late postoperative dysphagia and gas bloat syndrome was statistically lower in current study. **Conclusions:** Endoscopy during surgery enables the surgeon to check the wrap geometry, decreasing the rate of postoperative recurrence of GERD symptoms, post-operative dysphagia and decrease risk of esophageal perforation however prolongation operative time is the main side effect.

Key words: Gastroesophageal Reflux disease, Intraoperative Endoscopy, Antireflux Procedure.

Introduction

During infancy, gastroesophageal reflux disease (GERD) is the most frequent gastroenterologic illness resulting in referral to a paediatric gastroenterologist; Frequent transient lower esophageal relaxations characterize immature lower esophageal sphincter (LES) function, resulting in retrograde passage of stomach contents into esophagus^[1].

The angle of His is acute in newborns but declines as babies grow; hiatal hernia existence may push the lower esophageal sphincter (LES) into the thoracic cavity, Lower intrathoracic pressure may assist gastroesophageal reflux in conditions such as gastroparesis, gastric outlet blockage, and pyloric stenosis, when resistance to gastric outflow elevates intragastric tension and causes reflux^[2].

Typical symptoms of GERD in children include crying, disturbed sleep, and reduced eating. Other typical symptoms and signs in babies and young children involve weight loss or poor development (failure to thrive), vomiting, wheezy chest, chest or stomach discomfort, stridor, recurrent pneumonitis, diarrhea, throat soreness, laryngitis, hoarseness, persistent cough, Water erosion and Sandifer disease (ie, posturing with opisthotonus or torticollis)^[3].

The majority of paediatric gastroesophageal reflux cases are identified based on clinical symptoms. Experimentally, conservative steps may be initiated. However, additional investigation is required if the presentation is unusual or if the treatment response is inadequate. Esophageal manometry, esophagogastroduodenoscopy (biopsies may also be taken for histopathologic examination during

esophagogastroduodenoscopy), upper gastrointestinal scanning, and esophageal pH measurement It is not advised in instances of apparent gastroesophageal reflux but is effective for showing a link between reflux and symptoms in unconventional forms^[4].

80 percent of instances of GERD in newborns and very young children recover by age 18 months (55 percent recover by age 10 m), while some patients need a "step-up" to acid-reducing drugs. In situations where symptoms remain beyond 18 months, persistent GERD is suspected. In cases of resistant GERD or when problems such as stricture, aspiration, failure to thrive, or Barrett esophagus are found, surgical therapy is often required. The surgical prognosis is regarded as favorable^[5].

Antireflux treatment must be inserted around the distal two or three centimetres of the intraabdominal oesophagus without pressure to reestablish cardiac function. If the antireflux method is not geometrically accurate and adequately positioned, symptoms may linger or new issues may occur. Therefore, proper identification of GEJ is important to this procedure^[6].

Endoscopy, esophagograms and manometry aid in esophageal length preoperative measurement and aid in predicting GEJ position. Although these tests are useful, the definitive diagnosis of the gastroesophageal junction is achieved during surgery, that is currently most often performed via laparoscopy. Sometimes, it might be difficult to detect the precise site of the GEJ using laparoscopy^[7].

In this research, we anticipated that intraoperative evaluation of the appropriateness of the antireflux surgery and hiatus hernia repair with

reference to their optimal design would be aided by preoperative endoscopy. This information might be utilised to adjust the shape or location of the antireflux technique, hence increasing its likelihood of regaining cardia function.

Patients and Methods:

This prospective study included 30 patient of pediatric Age less than 18 years old with GERD resistant to conservative treatment. This study was conducted at Benha university hospital and Cairo University Specialized Pediatric Hospital at period from October, 2020 till October, 2022. The study was approved by the ethical committee of faculty of medicine. Informed written consents were obtained from the parents of all patients; all patients after informed consent were subjected to laparoscopic antireflux procedure. During treatment procedure, endoscopy had been used to locate GEJ and to assess tightness of performed valve.

Laparoscopic Nissen fundoplication was considered in GERD with failed medical treatment, Occurrence of complication as (failure to thrive, stricture, Barrett's esophagus, and respiratory complications) and Hiatus Hernia. But patients excluded from this study were GERD secondary to pyloric stenosis, duodenal atresia and esophageal atresia or Inability to accept possible complication of procedure.

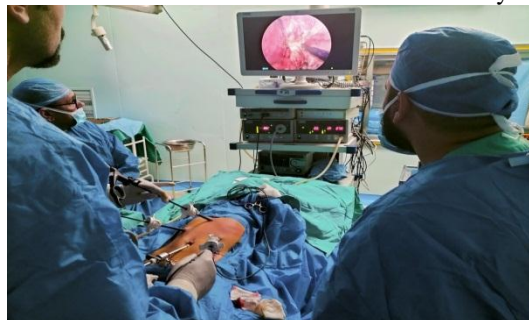

Fig. (1) Operative setting with the surgeon at the foot and the monitor at head of the table and Port sites.

A five mm port was used for the telescope introduction through umbilicus using the open technique, A five mm instrument was introduced in the left hypochondrium (midclavicular line) to be the surgeon's right working instrument, A five mm instrument was inserted by the closed method under visual guidance in the right hypochondrium (midclavicular line) for the left working instrument. Lastly, a five mm grasper was inserted without a port below the right costal margin laterally to apply traction on the stomach by the assistant.

To retract the left lobe of the liver thus exposing the hiatus, we used a (2/0) vicryl suture that was applied through the falciform ligament and the hiatus or sometimes we inserted a grasper below the xiphoid process.

All patients were evaluated for: history, physical examination and investigations. History and duration of Presenting complain like (Vomiting, Dysphagia, Hematemesis, Recurrent chest infections, Asthma, Apnea attacks, Failure to thrive), weight loss, history of prematurity, Previous surgery: (tracheo-esophageal fistula, previous antireflux procedure).

Physical examination: The patient's general condition, weight and height for age, abdominal masses and scars of previous surgeries were evaluated.

Preoperative investigations: Laboratory tests: Include complete blood count, Clotting profile, Lipid profile, Liver function tests; other investigations: upper endoscopy, esophageal manometry, esophageal PH monitoring and gastrograffin swallow and meal.

Operative technique:

Affixed with sticky tape, infants and little children were placed frog-legged at the foot of the operating table. The surgeon stood between the patient's legs. The assistant stood on the surgeon's right side to manage the stomach traction, while the cameraman sat on his left side, the monitor was positioned on the surgeon's right shoulder, and the endoscope was located on his left shoulder. The table was then placed in reversed trendelenburg to allow the intestine and colon to fall down exposing the upper abdominal cavity.

The peritoneum was insufflated with CO₂ to (8–12) cm H₂O depending on the size of the patient; a 30-degree angled five mm telescope was routinely used, by pulling the stomach in a left caudal direction the hepato-gastric ligament was put under traction. A device (Ligasure/Harmonic) was utilized to separate the phrenco esophageal ligament up to the oesophagus anterior wall and farther anteriorly across the right crus.

Complete fundus mobilization by division greater omentum along upper part of greater curvature of stomach and gastro splenic ligament containing short gastric vessel, Tension free mobilization of lower (3-5) cm of esophagus from posterior mediastinum, Crural repair by non-absorbable suture.

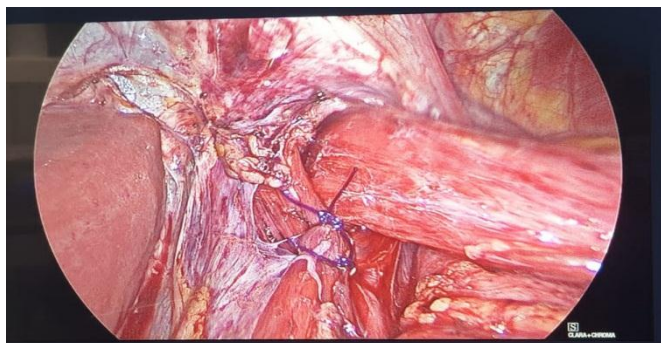


Fig. (2) Crural repair by polypropylene sutures.

Transorally, a flexible fibroptic endoscope was introduced. We identified esophagitis or Barrett's esophagus, the squamocolumnar connection position, and the GEJ by finding

the tubular esophagus end and the gastric rugal folds start. The endoscope was positioned precisely at that level, and then laparoscopically detected.

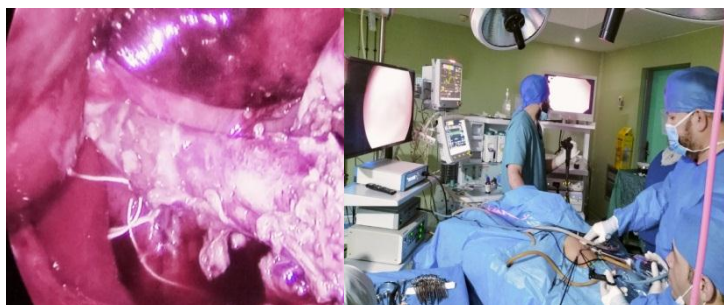

Fig. (3-4) determination of GEJ by endoscopic light source

The mobilized fundus was then gripped with the right hand and delivered through the posterior esophageal window, where it was accepted by a grasper held in the left hand and

guided gently to the esophagus right side. The "shoeshine" technique was then done to achieve a flexible, flaccid, and symmetric fundoplication around the esophagus.

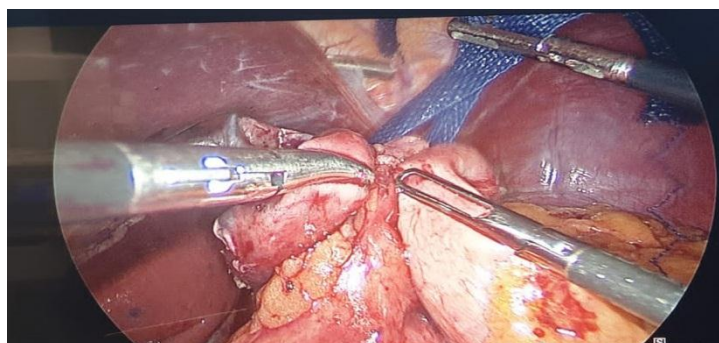


Fig. (5) shoe shine maneuver

Afterwards, a simple interrupted non-absorbable (2-0) Left-to-right sutures were applied to approximate the fundus encircling the oesophagus. A second stitch was put one centimetre above the first suture, encompassing the left part of the fundoplication, the leading edge of the fundoplication, esophagus and crura. Occasionally, a third suture was put around

one centimetre below the first. Fundoplication should not be performed with excessive force. Endoscopy was repeated (with the endoscope remaining in the midesophagus) following fundoplication to examine the characteristics of the fundoplication and the quality of the new flap valve. Subjective qualities like length, tightness, twisting, symmetry and redundancy were noticed.

Postoperative follow up:

Patients were evaluated early post-operatively for dysphagia, bloating (epigastric distension), Vomiting, Fever and respiratory distress and duration of hospital stay.

Patients were evaluated on late six months Post-operative follow up for dysphagia bloating (epigastric distension), vomiting, Ability to blench, Recurrence, weight gain and Parent's satisfaction.

Statistical methods:

Version 22 of the statistical package for the social sciences (SPSS) (IBM Corp., Armonk,

Results:

The obtained results were collected and tabulated:

NY, USA) was used to code and input data. Mean, standard deviation, median, minimum, and maximum were used to represent quantitative data, while frequency (count) and relative frequency (%) were used to summarize categorical data. Utilizing the non-parametric Mann-Whitney test, quantitative variables were compared. Chi square test was used for comparing categorical data. When the anticipated frequency is less than 5, the exact test is utilized. P-values less than 0.05 are regarded substantially significant.

Table (1) Distribution of the studied group according to demographic characteristics.

Demographic characteristics.	No (30)	%
Sex		
Male	20	66.7
Female	10	33.3
Age (year)		
Mean	5.13	
±SD	3.45	
Range	1.0-13.0	
Weight		
Mean	15.73	
±SD	6.45	
Range	7.0-35.0	
Neurological status		
Cerebral palsy	2	6.7
Normal	28	93.3

Table (2) Distribution of the studied group according to patient presentation.

Patient presentation	No (30)	%
Only GERD	2	6.7
Recurrent Hiatus hernia	2	6.7
Type(1) Hiatus hernia	20	66.7
Type (2) Hiatus hernia	1	3.3
Type(3) Hiatus hernia	4	13.3
Type (4) Hiatus hernia	1	3.3
Vomiting		
Yes	18	60.0
No	12	40.0
Hematemesis		
Yes	4	13.3
No	26	86.7
Chocking & cough		
Yes	14	46.7
No	16	53.3
Dysphagia		
Yes	5	16.7
No	25	83.3
HB		
Mean	10.27	
±SD	0.521	
Range	9.0-11.0	

Table (3) Distribution of the studied group according to early complications.

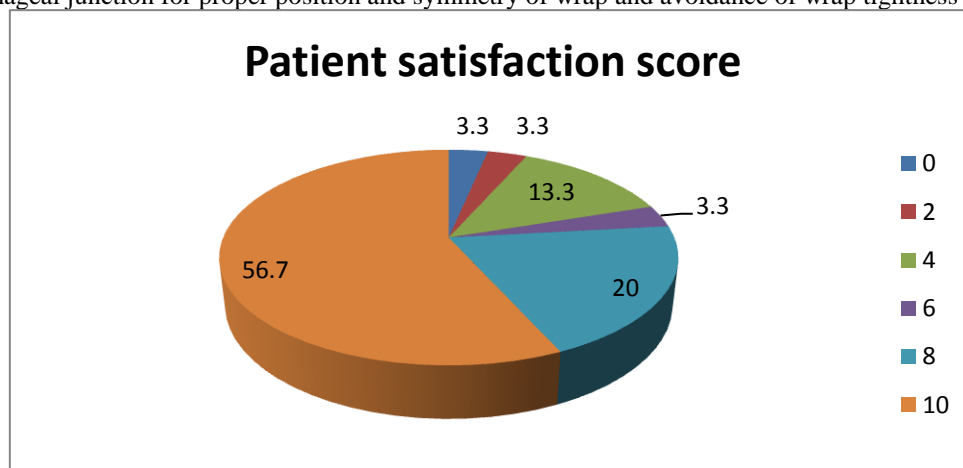
	No (30)	%
Esophageal perforation		
Yes	0	0
No	30	100
Vomiting		
Yes	3	10.0
No	27	90.0
Dysphagia		
Yes	7	23.3
No	23	76.7
Bleeding		
Yes	0	0
No	30	100
Pneumothorax		
Yes	0	0
No	30	100

There is significant decrease in early post-operative complication rate, P-values less than 0.05, as early dysphagia 23.3% which is d.t tissue edema, early vomiting 10%, no cases of post-operative bleeding or post-operative pneumothorax or esophageal perforation.

Table (4) Distribution of the studied group according to late complications.

	No (30)	%
Bloating		
Yes	3	10.0
No	27	90.0
Vomiting		
Yes	1	3.3
No	29	96.7
Dysphagia		
Yes	2	6.7
No	28	93.3
Recurrence		
Yes	2	6.7
No	28	93.3
Ability to blench		
Yes	25	83.3
No	5	16.7

Late postoperative dysphagia and gas bloat syndrome incidence was significantly lower in our study, P-values less than 0.05, due to use intraoperative endoscopy for accurate identification gastro esophageal junction for proper position and symmetry of wrap and avoidance of wrap tightness

**Fig. (6)** Distribution of the studied patients according to patient satisfaction score.

Discussion:

In several institutions throughout the globe, Nissen fundoplication is the most often used technique. This may be linked to its efficiency and positive long-term outcomes. Nevertheless, post-operative dysphagia and distention typically need a more physiologic fundoplication design. This is especially crucial for children, since their capacity to deal with uncomfortable symptoms is restricted⁽⁸⁾.

The hypothesis of the current study is whether the intraoperative endoscopy is of increasing effectiveness of Nissen fundoplication in addition to less dysphagia and bloating. The age of included children at time of operation varied widely between one year to 13 years old with median age of 5 years. This wide variation of age is similarly found in a large series by **Rothenberg** which included cases with an age range from 5 years to 18 years of age⁽⁹⁾.

In the current study, at the time of surgery, the body weights varied from as low as 8 kg to as high as 30 kg (mean, 15.7 ±6.4kg). Different reports included even a wider range of body weight such as by **Rothenberg** (12 to 120 kg) and **Esposito et al** (5 to 65 kg)^(9, 10).

A lot of concern has been raised for significantly increased intraoperative complications and anesthetic challenges in infants weighing less than 5 kg. However, recent reports ascertain that such procedure can be performed safely and effectively in neonates and young infants⁽¹¹⁾.

Patients enrolled in this research had a range of clinical manifestations. Frequently, many symptoms were seen. As mentioned in the results section, Vomiting that did not respond to medical therapy was the most prevalent presenting symptom, occurring in 60% of patients. Hematemesis with or without melena reflecting the presence of esophagitis was encountered in 13% of cases. Recurrent chest infections were present in 46% of cases. Hiatal hernia was present in about 93.5% of cases.

Mattioli et al reported that presenting manifestations was found persistent vomiting 63%, esophagitis 28%, repeated chest infection 18% and failure to thrive 29%. Otherwise, Rothenberg found that persistent vomiting 72%, esophagitis 7.6%, recurrent chest infection 26% and failure to thrive⁽¹²⁾.

In the current study, there is significant decrease in early post-operative complication rate, P-values less than 0.05, as early dysphagia 23.3% which is d.t tissue edema, early vomiting 10%, no cases of post-operative

bleeding or post-operative pneumothorax or esophageal perforation.

The use of intraoperative endoscopy prevents perforation because transillumination of the endoscope identifies the esophagus lumen, therefore facilitating dissection in the correct plane, particularly in cases with large and recurring hiatal hernia. In addition, using an endoscope to inflate the oesophagus enables the surgeon to examine the integrity of an esophageal restoration; nevertheless, the major adverse effect is an increase in operating time.

In a recent study that analyzed a population-based cohort of 2655 patients who underwent primary laparoscopic fundoplication between 2005 and 2014, it was found that 4.1% of the patients experienced complications within 30 days after the surgery. These complications included infection (1.1%), bleeding (0.9%), and esophageal perforation (0.9%). Additionally, around 50% of the patients experienced acute-onset dysphagia, which is believed to be a result of post-surgery edema and inflammation. However, this issue can be prevented by adopting certain measures. Keeping the wrap loose and floppy, dividing the upper short gastric vessels, and putting the patient on a soft diet for 2 to 3 weeks after the operation can help avoid dysphagia.⁽¹³⁾

In the present investigation, the duration of our surgery was much longer than that of Nissen fundoplication without intraoperative endoscopy. The mean duration in our study was 2 hours and (± 30 minutes) when compared to Nissen fundoplication without endoscopy which had a mean of 1.5 hours (±48 minutes) in the large retrospective study by **Esposito et al**⁽¹⁴⁾.

Moving to the outpatient follow up observations, the incidence of late postoperative dysphagia and gas bloat syndrome was significantly lower in current study due to use intraoperative endoscopy for accurate identification gastro esophageal junction for proper position and symmetry of wrap and avoidance of wrap tightness. Late postoperative dysphagia account 6.7%, gas bloat syndrome 16.7% and recurrence of GERD symptoms that need PPI 6.7%. **Kubiak and colleagues** conducted a prospective study involving 175 patients and reported a considerably higher incidence of dysphagia at 11.8% when a complete wrap was performed. However, it is worth noting that other studies have not found any significant relationship between dysphagia and the type of wrap used⁽¹⁵⁾.

In the present study, there is significant increase in post-operative weight, hemoglobin and parent satisfaction, parents of both groups

were asked to give a score (score of 1 to 10) comparing the general condition and activity of their children compared to the pre-operative status. This was recorded 6 months postoperatively. The mean score was around 10 in 76% of cases.

Conclusion

Endoscopy is a dependable and simple technique for precisely identifying the GEJ, particularly in cases of giant and recurrent hiatus hernia. Moreover, during the surgery, intraoperative endoscopy enables the surgeon to assess the wrap's anatomy and geometry, allowing easy corrections to be made. This leads to a reduction in postoperative GERD symptom recurrence caused by wrap failure, post-operative dysphagia, and the risk of esophageal perforation. Nevertheless, the main side effect is a potential increase in operative time.

References

- [1] Blanco FC, Davenport KP, and Kane TD: Pediatric gastroesophageal reflux disease. *Surg Clin North Am.* (2012) Jun. 92 (3):541-58, viii. doi: 10.1016/j.suc.2012.03.009.
- [2] Rosen R: Novel Advances in the Evaluation and Treatment of Children with Symptoms of Gastroesophageal Reflux Disease. *Front Pediatr.* (2022) Apr 1;10:849105. doi: 10.3389/fped.
- [3] Nilsson G, Larsson S, Johnsson F: Randomized clinical trial of laparoscopic versus open fundoplication: blind evaluation of recovery and discharge period. *Br J Surg.* (2000) Jul. 87 (7):873-8. doi: 10.1046/j.1365-2168.2000.01471.x.
- [4] Wenner J, Nilsson G, Oberg S, Melin T, Larsson S, Johnsson F: Short-term outcome after laparoscopic and open 360 degrees fundoplication. A prospective randomized trial. *Surg Endosc.* (2001) Oct; 15(10):1124-8. doi: 10.1007/s00464-001-9043-4.
- [5] Somme S, Rodriguez JA, Kirsch DG, Liu DC: Laparoscopic versus open fundoplication in infants. *Surg Endosc.* (2002) Jan;16(1):54-6. doi: 10.1007/s00464-001-8147-1.
- [6] Rangel SJ, Henry MC, Brindle M, Moss RL: Small evidence for small incisions: pediatric laparoscopy and the need for more rigorous evaluation of novel surgical therapies. *J Pediatr Surg.* (2003) Oct;38(10):1429-33. doi: 10.1016/s0022-3468(03)00491-3.
- [7] Rothenberg SS: The first decade's experience with laparoscopic Nissen fundoplication in infants and children. *J Pediatr Surg.* (2005) Jan; 40(1):142-6; discussion 147. doi: 10.1016/j.jpedsurg.2004.09.031.
- [8] Rosales A, Whitehouse J, Laituri C, Herbello G, Long J: Outcomes of laparoscopic nissen fundoplications in children younger than 2-years: single institution experience. *Pediatr Surg Int.* (2018) Jul;34(7):749-754. doi: 10.1007/s00383-018-4281-x.
- [9] Steven S Rothenberg , Donna Bratton: The effects of laparoscopic Nissen fundoplication to enhance pulmonary function in the treatment of a patient with severe asthma and gastroesophageal reflux disease. *J Allergy Clin Immunol.* (2008) Apr; 121(4):1069-70. doi: 10.1016/j.jaci.2008.02.027.
- [10] Esposito C, Montupet P, Reinberg O: Laparoscopic surgery for gastroesophageal reflux disease during the first year of life. *J Pediatr Surg.* (2001) May; 36(5):715-7. doi: 10.1053/jpsu.2001.22943.
- [11] Little DC, Rescorla FJ, Grosfeld JL, West KW, Scherer LR, Engum SA: Long-term analysis of children with esophageal atresia and tracheoesophageal fistula. *J Pediatr Surg.* (2003) Jun;38(6):852-6. doi: 10.1016/s0022-3468(03)00110-6.
- [12] Mattioli G, Pini-Prato A, Gentilino V, Caponcelli E, Avanzini S, Parodi S, et al.: Esophageal impedance/pH monitoring in pediatric patients: preliminary experience with 50 cases. *Dig Dis Sci.* (2006) Dec; 51(12):2341-7. doi: 10.1007/s10620-006-9374-z.
- [13] Wenner J, Nilsson G, Oberg S, Melin T, Larsson S, Johnsson F: Short-term outcome after laparoscopic and open 360 degrees fundoplication. A prospective randomized trial. *Surg Endosc.* (2001) Oct. 15(10):1124-8. doi: 10.1007/s00464-001-9043-4.
- [14] Till H, Esposito C, Escolino M, Singer G, Gasparella P, Arneitz C: Laparoscopic Treatment of Gastroesophageal Reflux Disease in Children: How We Do It. *J Laparoendosc Adv Surg Tech A.* (2021) Oct;31(10):1175-1179. doi: 10.1089/lap.2021.0401.
- [15] Skerritt C, Kwok CS, Kubiak R, Rees CM, Grant HW: 10 Year Follow-Up of Randomized Trial of Laparoscopic Nissen versus Thal Fundoplication in Children. *J Laparoendosc Adv Surg Tech A.* (2022) Nov; 32(11):1183-1189. doi: 10.1089/lap.2022.0083.