

Latarjet procedure Versus Free Iliac Graft in Management Of Recurrent Shoulder Dislocation With Bone Defect, A Comparative Study article review

Mohamed.M.Elwan, Mohamed.S.Shawky and EL-sayed.M.Bayomy

orthopedic surgery Dept., Faculty of Medicine Banha University

E-mail: midokingg1982@gmail.com

Abstract

Background: Over the last couple of decades, there has been much discussion on how best to manage patients with recurrent traumatic anterior glenohumeral instability. When dealing with bone loss due to repeated shoulder dislocation, Latarjet and Eden Hybinette are both excellent treatment options. In instances of recurrent shoulder dislocation with glenoid bone loss or Hill Sachs lesion of the humeral head, the goal of this study is to evaluate the functional outcomes of Latarjet against free tricortical iliac graft. **Cases and procedures:** Forty adult patients with repeated shoulder dislocations and bone loss participated in this prospective randomised controlled trial (RCT). Two groups of patients were selected at random. (twenty cases of Eden Hybinette and twenty handles for Latarjet aircraft). We compared the outcomes radiographically using CT after at least six months and clinically using the modified Rowe score. Potential side effects in both groups were also recorded. No clinically or radiographically significant differences were seen between the groups ($P > .05$). Latarjet group had significantly reduced ROM (particularly internal and exterior rotation) at the last follow-up ($P.05$). Tramadol caused repeated dislocation in one patient in the latarjet group. Two people in each set had solely frontal lobe anxiety. Ten percent of patients in the Eden group had donor-site sensory problems. On CT, the grafts in the iliac group seemed bigger. In conclusion, Latarjet and Eden Hybinette are two competing methods for regaining bone-loss-related shoulder stability, better ROM.

Keywords: Bone augmenting techniques, Latarjet procedure, Eden Hybinette procedure, Recurrent shoulder dislocation with bone loss

Introduction

Shoulder When it comes to diagnosing and treating joint problems, instability is among the most contentious. The most typical kind is the traumatic anterior type [1]. Shoulder dislocation occurs at a rate of 12 per 100,000 people annually, according to Thielemann and Holz; if repeated dislocations are included, the rate increases to 17 per 100,000 people annually. The anterior-inferior dislocation accounts for 95% of all shoulder dislocations, whereas the posterior dislocation accounts for 3% and the remaining forms account for 2% [2]. There is a significant failure rate after Bankart repair as a result of decreased shoulder congruency caused by neglect of bone loss [3,4]. This bone loss might be unipolar or bipolar. Latarjet technique is superior to iliac grafting because of its three-pronged impact (bony, ligamentous, and muscular) [5]. However, it's important to consider the potential drawbacks of Latarjet, such as reduced mobility, shoulder dyskinesia, neurovascular damage, revision surgery challenges, and the onset of glenohumeral arthritis. Eden Hybinette is often prescribed for patients with uncontrolled epilepsy, a significant glenoid defect more than 50 percent, or a failed Latarjet procedure. High-contour, non-immunogenic, and with osteoinductive and osteoconductive characteristics, autologous ICBG provides an almost infinite supply of graft [6]. Both Eden [7] and Hybinette [8] described it for the first time in 1918. Warner et al. [6] presented the intraarticular autologous tricortical iliac crest technique as a solution to the problems found with Latarjet. Osteolysis and donor-side

problems must be considered when using iliac grafts, despite the fact that they may yield greater graft material. side [9].

Aim Of This Work

To In situations of repeated shoulder dislocation resulting in significant glenoid bone loss or a humeral Hill Sachs lesion, the functional outcomes of Latarjet vs autologous free tricortical iliac graft should be compared. head.

Patients And Methods

Forty adult patients with recurrent shoulder dislocation and glenoid bone loss of more than 20% or hill sachs lesions of more than 25% participated in this randomised controlled trial (RCT). Each patient was randomly assigned to either the iliac grafting (case group) or Latarjet (control group) group until we had gathered twenty patients treated with the iliac grafting (case group) and twenty patients treated with the Latarjet (control group) (control group). Patients were selected at random from the Outpatient Departments of Benha University Hospital (Benha City, Egypt) and East Jeddah Hospital between December 2020 and May 2023. (Jeddah, Saudi Arabia). Patients' case records and signed informed consent forms were collected. All patients had a standard X-ray, CT (Figure 2), and MRI [10, 11]. Open Latarjet procedures using the method reported by Young et al. [12] or open ICBGT procedures using the method described by Warner [13] were randomly allocated to patients. Both sets of people are seated on a low beach chair. Both groups used a deltopectoral approach, but the Eden Hybinette

procedures also included an incision at the anterior iliac crest to collect grafts. During the Latarjet procedure, the pectoralis minor tendon is cut, the coracoid is osteotomized close to the base while leaving the conjoined tendon and parts of the coracoacromial ligament attached, the subscapularis is permanently split horizontally, the capsule is split vertically, the coracoid is transposed to the anterior glenoid rim flush with the glenoid articular surface, fixed with 2 screws, and After determining the size of the glenoid defect in Eden Hybinette, a tricortical iliac graft was taken from the patient and inserted intra-articularly with the inner table facing laterally. Two screws were used for fixation, and the horizontal split in the subscapularis was stitched back together (side by side). Patients were clinically monitored for a minimum of six months using the pain, stability, mobility, and function components of the modified Rowe scale [14]. At the conclusion of at least six months of follow-up, radiographic evaluation of the graft's healing was performed using X-ray and CT scans. Finally, we examined the outcomes for patients treated with Latarjet and Eden Hybinette. The information was evaluated statistically using SPSS (Statistical Package for the Social Sciences).28.0.1.1, 08 Feb 2022).

Clinical outcome assessment: preoperative Instability testing, such as the apprehension test [14] and the relocation test [15]; hyperlaxity evaluation utilising the Beighton score[16]; thorough case histories (first dislocation age, reasons, numbers, prior surgical repair, and bilateral affection). Testing the shoulder's strength was done by using dynamometer. Assessing the ROM was done by using Goniometer. Assessment of various types of instabilities such a dislocation, subluxation, apprehension positive or apprehension negative were done.

Inclusion Criteria:

It meant the following: (1) Traumatic anterior shoulder dislocation that occurs often. Two) Isolated incidents. (3) Individuals between the ages of 18 and 35. (4) Large engaging Hill Sacchs lesion (covering more than 25 percent of the humeral articular surface) or antero-inferior glenoid bony defect (covering more than 20 percent of the antero-posterior width). Five) Previously unsuccessful stability operation, such as a Bankartrepair).

Exclusion Criteria:

It was first, those who are prone to falling in many different directions. Glenohumeral dysplasia (2) patients. Three patients who also had a tear of the rotator cuff. Four) People who had a shoulder surgery instead of a stabilisation treatment in the past. (5) People who have broken the greater

tuberosity or the proximal humerus at the same time. (6) Individuals who suffer from unchecked neurological disorders (e.g. epilepsy). Paralytic dislocation, number seven. Instability Severity Score 6 in 8 or more patients Index (I.S.I.S) score [16].

Results

Both groups showed no significant differences regarding their preoperative characteristics including age, gender, dominance of the affected side, occupation, mechanism of trauma, hyperlaxity, age of first dislocation, number of dislocation, previous failed Bankart, and preoperative modified Rowe scores' means. Also no significant difference between pre-operative radiologic assessment including either glenoid bone loss or Hill Sachs sizes.

a. **Clinical outcome:** The difference between the method of postoperative global morphological change At the 6-month post-op follow-up, the difference between the Latarjet and iliac groups in terms of Rowe ratings was not statistically significant ($p=0.699$). Seventeen patients (85%) in the Latarjet group and eighteen patients (90%) in the iliac group reported satisfaction. ($p=1$) (Figure 1). Both exterior and internal rotation in the Latarjet group were restricted to 90 degrees ($P=0.028^*$ and $P=0.036^*$, respectively); this difference was statistically significant, however most observations were within 10 degrees (P of total motion between both groups = 0.042^*). One patient in the Latarjet group (5%) had recurrent dislocation after undergoing revision surgery using a free iliac graft to correct screw bending that developed after a second seizure. As a result of fresh, mild traumatic experiences, two patients in each group (10%) tested positive for fear only after surgery. One person in the Latarjet group had a superficial surgical site infection that required antibiotic treatment, irrigation, and debridement. Two patients had hematoma at the surgery site, but they healed well after receiving therapy. For subsequent follow-up, one patient had graft non-union without any obvious clinical consequences. Physiotherapy and medicine were able to alleviate the pain experienced by three individuals in the iliac graft group due to donor site discomfort. Two patients had sensory abnormalities around the donor-site scar (numbness on the upper lateral region of the thigh), but at 6 months follow-up, they had completely healed. Wound debridement, daily dressings, and antibiotic therapy were effective in curing the three cases of infection that occurred at the donor site.apy.

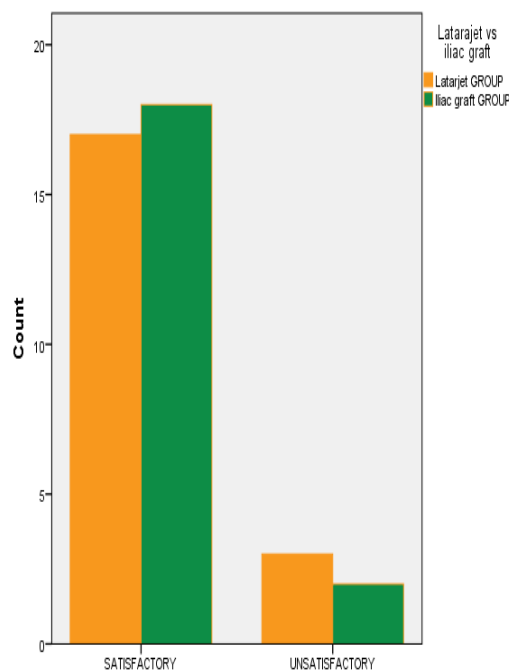


Fig. (1) Comparison between groups results regarding postoperative modified Rowe scores.

b. Radiologic outcome: post-operative glenoid The iliac graft augmentation considerably outperformed the Latarjet method in terms of surface area ($p=0.02$), defect area ($p=.003$), diameter ($p=.009$), depth ($p=.034$), and retroversion ($p=.002$). Eighty-three percent of ICBGT patients and sixty-eight percent of Latarjet patients were found to have off-track Hill-Sachs lesions prior to surgery ($P=0.206$). Only 14% of patients in the ICBGT group and 28% of patients in the Latarjet group had off-track abnormalities after surgery. ($P=0.310$).

Discussion

Both Latarjet & Eden Hybinette are golden modalities in reconstructing bone defects of recurrent shoulder dislocation.

Ideal graft position:

In our research, we found that it was best to position the coracoid graft directly on top of the glenoid rather than out to the side. Of the total number of grafts, 16 (80%) in the Latarjet group and 18 (90%) in the iliac graft group were flush with the glenoid. This finding was consistent with those of earlier research showing that the precise location of the coracoid graft is crucial in establishing long-term success. Although the ideal placement is hard to pin down, it is generally agreed that it should be neither too medial nor excessively lateral (less than 10 mm from the cartilage for some, less than 2 mm for others). In order to maximise the glenoid's articular surface, the bone blocks, according to some writers [17], should be completely flush. Additionally, Ghodadra et al. biomechanical investigation

suggests that normalising glenohumeral pressures may be achieved by fixing the graft flush with the glenoid. When the graft is fixed laterally by 2 mm or more, contact pressures rise [18]. Both groups' grafts are located at or below the equator (no grafts are located above the equator) and, according to Saito et al. [19], the average glenoid fracture on the right scapula occurs between 2:30 and 4:30. Similarly, Hovelius et al. [20] found that grafts located above the equator had a higher recurrence rate than those located below it. Radiographic evaluation and postoperative outcomes did not agree, according to research by Doursounian et al. CT scans [21].

There was no discernible difference in clinical (means of post-operative modified Rowe scores) or radiological (number of cancers detected) results between the two groups. This finding is in line with the literature; in a prospective randomised trial of 60 patients, Moroder et al. (Neer Award 2019) compared the clinical (WOSI and Rowe scores) and radiological (graft survival at 6, 12, and 24 months) outcomes of an open Latarjet graft transfer versus an iliac crest graft transfer. No significant changes were found in clinical or radiographic measures, and no differences were seen in measures of strength or range of motion, with the exception of decreased internal rotation in the Latarjet group. [6]. Both the Eden-Hybinette and Bristow-Latarjet techniques for glenoid bone augmentation for chronic anterior shoulder instability have been shown to have comparable clinical results [22, 23]. However,

the Eden-Hybinette surgery has a lower risk of neurological sequelae. It is probable that the permanent split of the subscapularis by the conjoined tendon at 90 degrees of abduction, particularly if the tendon is loaded rather than unloaded, accounts for the statistically significant difference in range of motion between the Iliac and Latarjet groups.

Patient age, sex, side, shoulder dominance, employment, generalised hyperlaxity, time interval before surgery, number of dislocations, number of dislocations during follow-up, post-operative physiotherapy, and duration of follow-up had no effect on results in either group. Furthermore, our research was limited in its ability to accurately identify the progression of arthropathy because of the short follow-up time [24]. In terms of postoperative stability, there was no discernible difference between the groups. This is consistent with the findings of earlier case series publications [25, 26] that demonstrated the high success rate of stabilisation of both operations even over the long term.

Donor site discomfort affected 15%, sensory abnormalities affected 10%, superficial wound infection affected 15%, and an extra pelvic scar affected 15% of those in the ICBGT group, despite the fact that the shoulder-related adverse event incidence was relatively low [27].

CT images taken soon after surgery demonstrated the ICBGT's successful augmentation of the glenoid. In contrast to the Latarjet graft, which is constrained by the size of the patient's coracoid process [28], the ICBGT is restricted by the size of the patient's iliac crest, which provides a greater bone supply. However, the limited duration of our investigation precluded us from detecting more osteolysis and resorption of the iliac bone.raft [29].

Conclusion

No Except for the Latarjet group's restricted range of motion (external and internal rotation), there were no clinically or radiographically detectable differences between the two groups. The success rate was high (85% and 90% respectively), which is promising, although the follow-up time was brief. Whether you want to know if the outcomes will hold up over time, you should monitor these patients for longer. Additional research with a bigger sample size is required to definitively identify the elements influencing the result. Patients that have a history of taking part in sports greater compliance with the rehabilitation programme

and earlier return to activities compared to individuals who did not participate in sports

References

- [1] Phillips BB. Recurrent dislocations. In: Canale ST (ed). *Campbell's operative orthopaedics*. 10thed. St. Louis: Mosby; 2003. 2377- 448.
- [2] Thielemann FW, Holz U. Differential diagnosis of shoulder dislocation with special reference to posterior dislocation. *Aktuelle Traumatol* 1989; 19(6): 274–80.
- [3] Burkhart SS, De Beer JF. Traumatic glenohumeral bone defects and their relationship to failure of arthroscopic Bankart repairs: Significance of the inverted-pear glenoid and the humeral engaging Hill-Sachs lesion. *Arthroscopy* 2000; 16(7): 677-94.
- [4] Sugaya H, Moriishi J, Dohi M. Glenoid rim morphology in recurrent anterior glenohumeral instability. *J Bone Joint Surg Am*; 2003. 85:878-884.
- [5] Giles J, Boons H and Elkinson I. Does the dynamic sling effect of the Latarjet procedure improve shoulder stability? A biomechanical evaluation. *J Shoulder Elbow Surg*; 2013. 22: 821-8.
- [6] Moroder P, Schulz E, Wierer G, et al. Latarjet procedure versus iliac crest bone graft transfer for treatment of anterior shoulder instability with glenoid bone loss: a prospective randomized trial. *J Shoulder Elbow Surg.*; 2019. 28 (8):e280.
- [7] Eden R: Zur Operations der habituellen Schulterluxation unter Mitteilung eines neuen Verfahrens bei Abriss am inneren Pfannenrande. *Deutsch Ztschr Chir* 1918. 144:268-280.
- [8] Hybinette S: De la transplantation d'un fragment osseux pour remedier aux luxations recidivantes de l'épaule; constatations et resultants operatoires. *Acta Chir Scand* 1932. 71:411- 445.
- [9] Lennart Hovelius, Anders Olofsson, Björn Sandström, Bengt, Göran Augustini, Lars Krantz, et al. Nonoperative treatment of primary anterior shoulder dislocation in patients forty years of age and younger: a prospective twenty-five-year follow-up. *J Bone Joint Surg Am*; 2008. 90: 945-952.
- [10] Baudi P, Righi P, Bolognesi D, et al. How to identify and calculate glenoid bone deficit. *Chir Organi Mov*. 2005.90:145-52.
- [11] Gross ML, Seeger LL, Smith JB, et al. Magnetic resonance imaging of the glenoid labrum. *Am J Sports Med* 1990; 18 (3):229-34.
- [12] Young AA, Walch G. Open bony augmentation of glenoid bone loss– The

- Latarjet and variants. In: *Shoulder instability: A comprehensive approach*. Philadelphia: Elsevier, 2011; 197-208.
- [13] Warner JJ, Gill TJ, O'Hollerhan J D et al (2006): Anatomical glenoid reconstruction for recurrent anterior glenohumeral instability with glenoid deficiency using an autogenous tricortical iliac crest bonegraft. *Am J Sports Med*; 34:205-212.
- [14] Rowe CR, Zarins B. Recurrent transient subluxation of the shoulder. *J Bone Joint Surg (Am)* 1981; 63(6-A):863-72.
- [15] Jobe FW, Kvitne RS, Giangarra CE. Shoulder pain in the overhand or throwing athlete. The relationship of anterior instability and rotator cuff impingement. *Orthop Rev* 1989; 18:963-75.
- [16] Baum J, Larsson LG. Hypermobility syndrome-new diagnostic criteria. *J Rheumatol* 2000; 27:1585-6.
- [17] Mercier N and Saragaglia D. Mini-Open Latarjet Procedure for Recurrent Anterior Shoulder Instability. *Advances in Orthopedics* 2011; 65:205- 11.
- [18] Ghodadra N, Gupta A, Romeo AA, et al: Normalization of glenohumeral articular contact pressures after Latarjet or iliac crest bone-grafting. *J Bone Joint Surg Am* 2010; 92(6):1478-1489.
- [19] Saito H, Itoi E, Sugaya H, et al (2005) Location of the glenoid defect in shoulders with recurrent anterior dislocation. *Am JSports Med* 33:889–893.
- [20] Hovelius L, Sandström B, Olofsson A, Svensson O, Rahme H: The effect of capsular repair, bone block healing, and position on the results of the Bristow Latarjet procedure (study III): Long term follow-up in 319 shoulders. *J Shoulder Elbow Surg* 2012; 21 (5):647-660
- [21] Doursounian L, Debet-Mejean A, Chetboun A and Nourissat G. Bristow-Latarjet procedure with specific instrumentation: study of 34 cases. *International Orthopaedics (SICOT)* 2009; 33:1031–7.
- [22] Bockmann B, Venjakob AJ, Reichwein F, Hagenacker M, Nebelung W. Mid-term clinical results of an arthroscopic glenoid rim reconstruction technique for recurrent anterior shoulder instability. *Arch Orthop Trauma Surg*. 2018.138(11):1557–62.
- [23] Longo UG, Loppini M, Rizzello G et al (2014) Latarjet, Bristow, and Eden- [31] 0363546512446681.
- Hybinette procedures for anterior shoulder dislocation: systematic review and quantitative synthesis of the literature. *Arthrosc J Arthrosc Relat Surg Off Publ Arthrosc Assoc N Am Int Arthrosc Assoc* 30:1184–1211.
- [24] Beran MC, Donaldson CT, Bishop JY (2010) Treatment of chronic glenoid defects in the setting of recurrent anterior shoulder instability: a systematic review. *J Shoulder Elb Surg* 19:769–780.
- [25] Gordins V, Hovelius L, Sandström B, Rahme H, Bergström U. Risk of arthropathy after the Bristow-Latarjet repair: a radiologic and clinical thirty-three to thirty-five years of follow-up of thirty-one shoulders. *J Shoulder Elbow Surg* 2015; 24:691-9. <https://doi.org/10.1016/j.jse.014.09.021>.
- [26] Mizuno N, Denard PJ, Raiss P, Melis B, Walch G. Long-term results of the Latarjet procedure for anterior instability of the shoulder. *J Shoulder Elbow Surg* 2014; 23:1691-9. <https://doi.org/10.1016/j.jse.2014.02.015>.
- [27] Moroder P, Hitzl W, Tauber M, Hoffelner T, Resch H, Auffarth A. Effect of anatomic bone grafting in post-traumatic recurrent anterior shoulder instability on glenoid morphology. *J Shoulder Elbow Surg* 2013; 22 :1522-9. <https://doi.org/10.1016/j.jse.2013.03.006>.
- [28] Dimitriou R, Mataliotakis GI, Angoules AG, Kanakaris NK, Giannoudis PV. Complications following autologous bone graft harvesting from the iliac crest and using the RIA: a systematic review. *Injury* 2011;42(Suppl 2):S3-15. <https://doi.org/10.1016/j.injury.2011.06.015>.
- [29] Ljungquist KL, Butler RB, Griesser MJ, Bishop JY. Prediction of coracoid thickness using a glenoid width-based model: implications for bone reconstruction procedures in chronic anterior shoulder instability. *J Shoulder Elbow Surg* 2012;21:815-21. <https://doi.org/10.1016/j.jse.2011.10.006>.
- [30] Moroder P, Hirzinger C, Lederer S, Matis N, Hitzl W, Tauber M, et al. Restoration of anterior glenoid bone defects in posttraumatic recurrent anterior shoulder instability using the J-bone graft shows anatomic graft remodeling. *Am J Sports Med* 2012;40: 1544-50. <https://doi.org/10.1177/>