

Diagnostic aspects of multidetector CT in detection of coronary artery diseases versus interventional coronary Angiography

H.M.Farouk¹, I.M.Helmy² and H.F.Ibrahim³

¹Radiodiagnosis, Dept., Faculty of Medicine, Kafr El-Sheikh Univ., Kafr El-Sheikh, Egypt

²Radiology, Dept., National Heart Institute, Cairo, Egypt

³Radiodiagnosis, Dept., Faculty of Medicine, Cairo Univ., Cairo, Kasr Al-Ainy

E-mail: Drhanyfathy452@gmail.com

Abstract

Background: Invasive coronary angiography (ICA) is the accepted reference standard for the assessment of coronary artery stenoses because of its unprecedented temporal and spatial resolution and the ability to perform therapeutic interventions in the same session. Although the associated risk for serious complications is small. The inconvenience for the patient and economic deliberations have strengthened the search for a non-invasive alternative. Current multi-slice computed tomography (MSCT) scanners provide promising results in the assessment of coronary artery disease (CAD). Coronary CT angiography using 64-slices has been shown in studies to have a high accuracy when using conventional coronary angiography as the reference standard. The aim of this study was to Evaluate the different diagnostic aspects of non-invasive computed tomography (CT) coronary angiography in ischemic heart diseased patients and its cost benefit in comparison to invasive coronary angiography in diagnosis of various Coronary Artery diseases (CAD). **Methods:** This study was conducted on 20 patients suffering from symptoms related to coronary artery diseases CAD. Patients had undergone ECG gated MDCT coronary angiography in CT unit in Radiology Department of National Heart Institute NHI and were analyzed from PACS (Syngovia acquisition system). This study included patients for detection of all sorts of coronary artery diseases compared to the results of invasive coronary Angiography attached with the patients including patients had been subjected for previous CABG operations. **Results:** In the present study There mean age of patients was 58 ± 8.1 years. and 16 patients (80%) were males and 4 patients (20%) were female. According to Risk factors of CAD in study population Diabetes mellitus was founded in 13 patients (65)%, Hypertension in 9 patients (45)%, Hyperlipidemia in 14 patients (70)%, Current smoker in 15 patients (75)%, Family history of CAD in 11 patients (55)%, and Obesity in 3 patients (15)%. In our patient population, the medical data Heart rate (beats/min) was 67 ± 8.4 and Calcium score (Agatston) was 307.4 ± 57.1 , while Prior myocardial infarction was founded in 5 patients (25%) and Previous PCI in 4 patients (20%). One patient (5%) has previous CABG. 40% of our study population showed coronary arteries' Anomalies. Acute angle of RCA was showed in 15% patients, RCA arising from LAD in 10% of patients, Posterior oriented origin of LAD from LCC in 5% of patients and Accessory LAD arising from RCA in 10% of patients. Validity of MDCT angiography in diagnosis of CAD, it showed a dependable accuracy when referred to interventional Catheter Coronary angiography as a gold standard (93.06%) and the most accurate findings was to Left Main Trunk artery. **Conclusion:** The use of noninvasive 64- slice CT coronary angiography as a vascular imaging technique can be performed rapidly and safely for the assessment of many different pathologies involving coronary arteries with a high diagnostic accuracy.

Key words: multidetector CT, coronary artery diseases, interventional coronary Angiography.

1. Introduction:

Topping the list of the world's most deadly diseases is Ischaemic heart disease IHD, more commonly known as Coronary Artery Disease CAD. Responsible for nearly millions of deaths every year, is caused by a build-up of fatty deposits on the wall of the arteries, usually attributed to lifestyle choices or other high risk conditions such as high blood pressure or diabetes. This disease is deadly as the patient's arteries become narrowed, restricting blood and oxygen flow to the heart, potentially leading to a fatal heart attack. Non-deadly attacks cause chest pain known as angina, which can proceed a heart attack. Hence, it is necessary to investigate about CAD by different modalities, one of them is Coronary CT angiography. ⁽¹⁾

Contrast-enhanced cardiac CT angiography (CTA) involves the use of multi-slice CT and intravenously administered contrast material to obtain detailed images of the blood vessels of the heart. Beta-blockers and sublingual nitrates may be administered prior to the scan in order to lower the heart rate, avoid arrhythmia and dilate the coronary arteries. In order to allow an improved image quality and contrast media as

well as radiation dose reduction, the CCTA is usually ECG-triggered to adapt the scan sequence to the person's heartbeat ⁽²⁾.

There is increasing evidence to show that coronary CT angiography represents the most rapidly developed imaging modality in cardiac imaging. Coronary CT angiography has high diagnostic value in the diagnosis of coronary artery disease due to rapid advances in multislice CT scanners. Furthermore, coronary CT angiography has demonstrated incremental prognostic value beyond clinical risk factors and allows for a quantification of the risk associated with coronary plaque in coronary CT angiography. ⁽³⁾

Spectacular advances in CT technology over the last decade has enabled faster scanning times, with sections as thin as 0.5mm and temporal resolution as low as 105 milliseconds can be obtained using multidetector CT. These developments have enabled acquisition of high quality angiographic images of heart in a single breath hold. Potential applications of coronary angiography with multi-detector row CT (MDCT) are diagnosis of coronary artery disease, coronary artery anomalies in origin, course and detection of myocardial bridging. ⁽⁴⁾

The current challenges in performing coronary CT angiography have made the imaging technique to improve by using latest CT technology which provides an attractive alternative to invasive coronary angiography in routine clinical practice. With further developments in CT technology, coronary CT angiography will continue to play an important role in the diagnostic evaluation of coronary artery disease and prediction of major adverse cardiac events.⁽⁵⁾

The aim of this study was to Evaluate the different diagnostic aspects of non-invasive computed tomography (CT) coronary angiography in ischemic heart diseased patients and its cost benefit in comparison to invasive coronary angiography in diagnosis of various Coronary Artery diseases (CAD).

2. Patients and Methods

- **Type of the study:**

Descriptive Observational study.

- **Patients:**

Twenty patients were included in this study .

Patients had undergone ECG gated MDCT coronary angiography in CT unit in Radiology Department of National Heart Institute NHI and were analyzed from PACS (Syngovia acquisition system). This study included patients for detection of all sorts of coronary artery diseases compared to the results of invasive coronary Angiography attached with the patients including patients had been subjected for previous CABG operations .

- The study was approved by the Ethics Committee of the Institute and informed consent will be obtained from the patients.

Inclusion criteria:

Patients with coronary artery diseases CAD symptoms with their attached “invasive coronary Angiography “ reports.

Exclusion criteria:

1. Patients with impaired renal function.
2. Patients that have allergy to contrast.
3. Cardiac Arrhythmias as Persons in atrial fibrillation (except when rate-controlled or with other significant arrhythmia).
4. Ejection fraction less than 30% .
5. Pregnant Females .
6. Body mass index (BMI) greater than 40 (except when 3rd generation Dual-Source CT (DSCT) 120-kv tube voltage is utilized).
7. Calcium score 1000 or more .

Methods

Patient Preparation:

- Reassurance of the patient .
- Shaving of the chest hair .
- Respiratory training .
- Patients were asked to fast 4-6 hours prior to the examination.
- Medications are not to be discontinued .
- The heart rate was evaluated before the examination. The examination was done if the heart rate is below 70 beats per minute.

- Patients with heart rates above 70 beats per minute were given cardio-selective beta-blocker; 50/100 mg of Metoprolol or Bisoprolol or Atenolol orally 1 hour before the study to obtain a stable low heart rate, provided that there is a contra-indications to β -blockers.
- If the heart rate was still above 70 beats per minutes, the examination was postponed to another setting.
- Temporary coronary vasodilator (or coronary antispasmodic) for coronary spasm as Sublingual 5 mg Nitrates (Dinitra) at the scan time .
- To evaluate patients ability of breath-withholding for relatively long time; they were required to perform a deep inspiration and to continue to hold their breath without pushing (i.e., Valsalva maneuver). During this trial, the patient was observed for compliance and the ECG for significant changes.

Contrast Material:

A bolus of 120 ml of water soluble non-ionic contrast (*Omnipaque* 300 mg Daiichi Pharmaceutical, Tokyo, Japan), was injected through 18 gauge cannula into an upper limb vein – *noting that in patient that had been underwent CABG we have used 2 bottles of Omnipaque 300 mg* – injected through (right antecubital vein in all our cases to reduce left sided artifacts) with a flow rate of 5 to 5.5 mL/sec. This injection was automatically followed by injection of about 40-50 cc of saline at a flow rate of 5 ml/sec using a programmed dual head power injector pump (MedRad; USA) to maintain good opacification of the coronary vessels and the grafts with wash out of contrast material from the SVC and right side of the heart that may cause artifacts.

Reconstruction:

The data sets are reconstructed (with a slice thickness of 0.625mm and 0.4 mm increments) during the mid to end diastolic phase, 45-75% of the R-R interval. If image quality in this data set is not being optimal, additional reconstructions (35-85%) is performed and the data sets with optimal images will be chosen for further evaluation.

All acquired data is transferred to separate computer workstation. Depending on vessel morphology and quality of the MDCT data sets, different post processing techniques such as maximum-intensity projection (MIP), curved multiplanar reconstruction (CPR) and volume rendering (VR) are applied to assess the origin and course of the coronary arteries. We use an upper limit of heart rate of 75 beat per minute.

Padding of the tube-on time is used to allow the reconstruction to adapt to minor heart rate variation. Padding is ranged from 40 to 80 msc.

Dose-length-product (DLP) is recorded from the CT scanner for each patient. The effective radiation dose (E) in msv is calculated using the formula $E = DLP \times K$. The k is the conversion factor and is equal to 0.017. This k value is considered applicable for chest and cardiac scans.

MDCT coronary angiography examination (image acquisition)

Multi detector CT coronary angiography was performed using 64 slices CT, Ingenuity Core TM, Philips, Netherlands, and 64 slices CT GE optima 660 depending on ECG gated acquisition during a single breath hold.

2.1. Statistical analysis

Data management and statistical analysis were done using SPSS version 25. (IBM, Armonk, New York, United States). Quantitative data were assessed for normality by the Shapiro-Wilk test and direct data visualization methods. Numerical data were summarized

as means and standard deviations or medians and ranges. Categorical data were summarized as numbers and percentages. The number and properties of lesions was compared between MDCT angiography and interventional catheter angiography using Wilcoxon signed ranks test. The size of the smallest lesions was compared using paired t-test. All statistical tests were two-sided. P values less than 0.05 were considered significant.

3. Results

There mean age of patients was 58 ±8.1 years and 16 patients (80%) were males and 4 patients (20%) were female (Table 1).

Table (1) General characteristic

Age (years)	Mean ±SD	58 ±8.1
	Males n (%)	16 (80)
Gender	Females n (%)	4 (20)
BMI	mean ± SD	28.3 ± 6.4
Total		20

According to **Risk factors of CAD in study population** Diabetes mellitus was founded in 13 patients (65) % , Hypertension in 9 patients) 45(%, Hyperlipidemia in 14 patients (70)%, Current smoker in 15 patients (75)%, Family history of CAD in 11 patients (55)%, and Obesity in 3 patients (15)% (Table 2).

Table (2) Risk factors of CAD in study population.

Risk factors	Diabetes mellitus	n (%)	13 (65)
	Hypertension	n (%)	9 (45)
	Hyperlipidemia >70%	n (%)	14 (70)
	Current smoker		15 (75)
	Family history of CAD		11 (55)
	Obesity		3 (15)
Total			20

In our patient population, the medical data Heart rate (beats/min) was 67 ± 8.4 and Calcium score (Agatston) was 307.4 ± 57.1, while Prior myocardial infarction was founded in 5 patients (25%) and Previous PCI in 4 patients (20%). One patient (5%) has previous CABG (Table 3).

Table (3) Medical data in study population.

medical history	Heart rate (beats/min)	mean ± SD	67 ± 8.4
	Calcium score (Agatston)	mean ± SD	307.4 ± 57.1
	Prior myocardial infarction	n (%)	5 (25)
	Previous PCI	n (%)	4 (20)
	Previous CABG		1 (5)
Total			20

40% (8 patients) of our study population showed coronary arteries' Anomalies. **Acute angle of RCA was showed in 15% patients, RCA arising from LAD in 10% of patients, Posterior oriented origin of LAD from LCC in 5% of patients and Accessory LAD arising from RCA in 10% of patients** (Table 4).

Table (4) Anomalies of coronary arteries detected by MDCT angiography

Coronary arteries' Anomalies	Acute angle of RCA	n (%)	3 (15)
	RCA arising from LAD	n (%)	2 (10)
	Posterior oriented origin of LAD from LCC	n (%)	1 (5)
	Accessory LAD arising from RCA	n (%)	2 (10)
Total			8 (40)

Validity of MDCT angiography in diagnosis of CAD, it showed a dependable accuracy when referred to interventional Catheter Coronary angiography as a gold standard (93.06%) and the most accurate findings was to Left Main Trunk artery. Analysis and Validity of MDCT angiography in diagnosis of CAD was showed in details in Table (5).

Table (5) Analysis and Validity of MDCT angiography in diagnosis of CAD.

MDCT Validity test	Right Coronary	Left Main Trunk	Left Anterior Descending	circumflex	total
True positive	10	8	13	9	40
True negative	6	12	5	8	31
False positive	1	0	0	1	2
False negative	3	0	2	2	7
Sensitivity	76.92%	100.00%	86.67%	81.82%	85.11%
Specificity	85.71%	100.00%	100.00%	88.89%	93.94%
Positive Likelihood Ratio	5.38	--		7.36	14.04
Negative Likelihood Ratio	0.27	--	0.13	0.20	0.16
Positive Predictive Value	37.43%	100.00%	100.00%	45.00%	60.94%
Negative Predictive Value	97.10%	100.00%	98.54%	97.78%	98.27%
Accuracy	84.84%	100.00%	98.67%	88.18%	93.06%

Case presentation

A 66-years old male patient presented with chronic typical angina pain

MDCT coronary angiography findings:

- LAD: mid. segment 50% stenosis
- LCX: no plaques or stenosis detected by revisor
- RCA : Atherosclerotic changes with long segment complete occlusion with good distal opacification likely retrograde filling

Cardiac catheterization angiography:

- LAD: Atherosclerotic changes with mid. segment 90% stenosis
- LCX: Atherosclerotic changes with distal segment 70% stenosis
- RCA : Atherosclerotic changes with complete occlusion with retrograde filling from It system

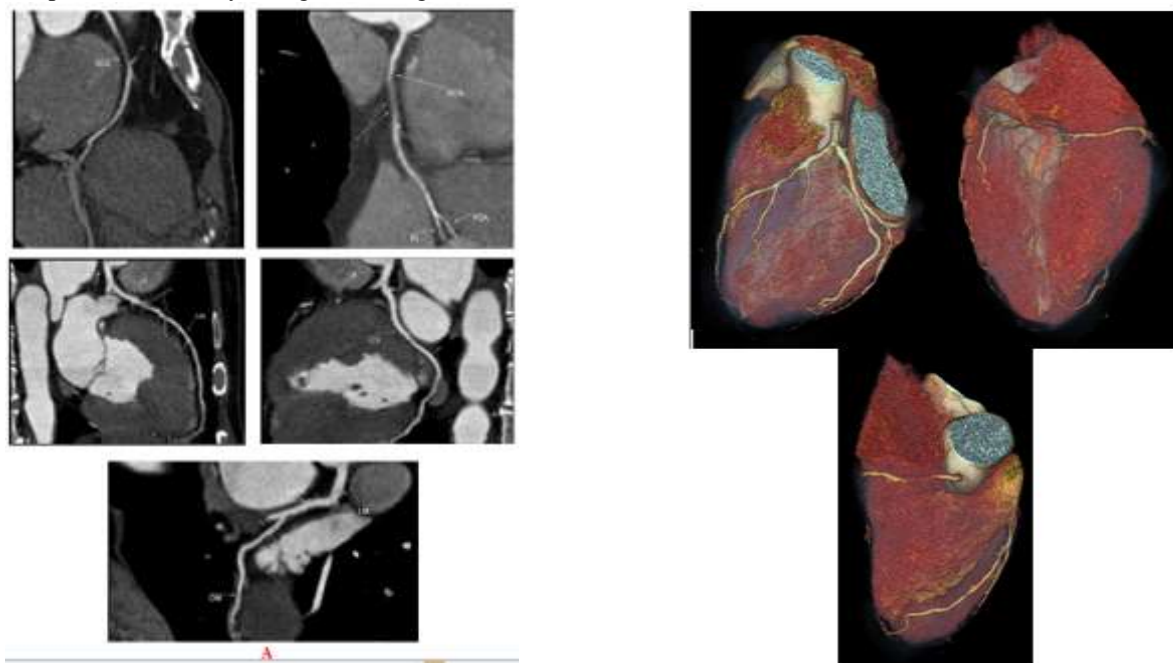


Fig. (1) MDCT angiography of case 1: A: MPR images. B: VRT images

A 45-years old male patient presented with chronic atypical angina pain and LAD can't be cannulated by Cardiac catheterization angiography

Cardiac catheterization angiography:

- LAD: mid segment total occlusion failed to be cannulated
- For referral to MDCT angiography team

MDCT coronary angiography findings:

- LAD: mid segment total occlusion
- LCX: calcified plaque causing significant stenosis
- RCA: non-significant soft plaque

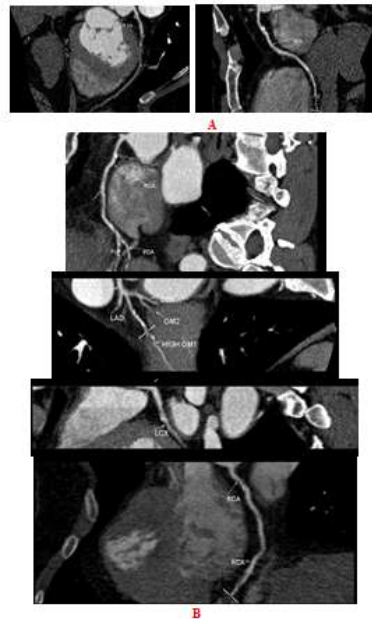


Fig. (2) MDCT angiography of case 5: A: MPR images. B: MIB image.

A 44-years old male patient presented with chronic atypical angina pain and Cardiac catheterization angiography team needed consultation of MSCT

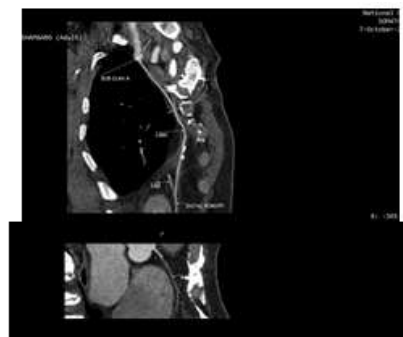
Cardiac catheterization angiography:

- LAD: medium artery with mid segment focal lesion with 80% stenosis
- LCX: atherosclerotic vessel with proximal total occlusion with occluded graft

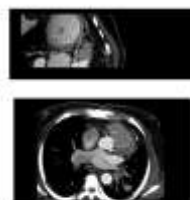
- RCA: atherosclerotic vessel with proximal total occlusion and retrograde filling

MDCT coronary angiography findings:

- LAD: atherosclerotic vessel with total occlusion received LIMA graft with good distal run off
- LCX and RCA totally occluded by SVG grafts



MPR



MIP



VRT

4. Discussion

In the present study There mean age of patients was 58 ± 8.1 years. and 16 patients (80%) were males and 4 patients (20%) were female . It was in the same line with Leschka et al.,⁽⁶⁾ study, where CT angiography was performed in 67 patients (50 male, 17 female; mean age 60.1 ± 10.5 years) with suspected coronary artery disease and compared with invasive coronary angiography

Also in Rakhawy et al.,⁽⁷⁾ A Total 100 patients were included 76 males and 24 females were evaluated with suspected coronary heart diseases; with mean age of the study group was 53.51 ± 11.6

According to Risk factors of CAD in study population Diabetes mellitus was founded in 13 patients (65) % , Hypertension in 9 patients (45)%, Hyperlipidemia in 14 patients (70) % , Current smoker in 15 patients (75)%, Family history of CAD in 11 patients (55) % , and Obesity in 3 patients (15)%

It was close to Rakhawy et al.,⁽⁷⁾ study, where the risk factors percentage as the following Smoking (72%), Dyslipidemia (69%), Diabetes mellitus (67%), Positive family history of CAD (51%), Hypertension (44%), and Obesity (13%).

In our patient population, the medical data Heart rate (beats/min) was 67 ± 8.4 and Calcium score (Agatston) was 307.4 ± 57.1 , while Prior myocardial infarction was founded in 5 patients (25%) and Previous PCI in 4 patients (20%). One patient (5%) has previous CABG

In Kuettnner et al.,⁽⁸⁾ study, Calcium score (Agatston) was 340 which was close to our results and Heart rate (beats/min) was 67.2 ± 11.3 . in Pundziute et al.,⁽⁹⁾ study Previous MI was found in 33 % of patients and Previous revascularization was done in 31% of patients.

40% of our study population showed coronary arteries' Anomalies. Acute angle of RCA was showed in 15% patients, RCA arising from LAD in 10% of patients, Posterior oriented origin of LAD from LCC in 5% of patients and Accessory LAD arising from RCA in 10% of patients.

Coronary artery anomalies and course were better detected using CT-coronary angiography than catheter coronary angiography in our study although the cases were less. Multi– detector computed tomography (MDCT) allows accurate and noninvasive depiction of coronary artery anomalies of origin, course, and termination. Multi– detector row CT is superior to conventional angiography in delineating the ostial origin and proximal path of an anomalous coronary^(10; 11; 12).

According to Validity of MDCT angiography in diagnosis of CAD in the present study, it showed a dependable accuracy when referred to interventional Catheter Coronary angiography as a gold standard (93.06%) and the most accurate findings was to Left Main Trunk artery.

In the same line with Leschka et al.,⁽⁶⁾ study in 2005 who used CT scans were performed on a 64-slice scanner with a 0.37 s rotation time (Somatom Sensation 64, Siemens, Forchheim, Germany). A bolus of 80 mL iodixanol (Visipaque 320 mg/mL, Amersham Health,

Buckinghamshire, UK) was injected into an antecubital vein at a flow rate of 5 mL/s, followed by a 50 mL saline chasing bolus. Overall sensitivity for classifying stenoses was 94%, specificity was 97%, positive predictive value was 87%, and negative predictive value was 99%.

Also in Nikolaou et al.,⁽¹³⁾ study who aimed to evaluate Accuracy of 64-MDCT in the Diagnosis of Ischemic Heart Disease. Sixty-eight of 72 coronary CT angiograms (CTAs) (94%) were of diagnostic image quality. QCA showed significant CAD (i.e., one or more stenoses in > 50%) in 57% (39/68) and nonsignificant disease or healthy CTAs in 43% (29/68) of the patients. Sensitivity, specificity, and the negative predictive value (NPV) of 64-MDCT per patient were 97%, 79%, and 96%, respectively. Per segment, 923 of 1,020 coronary artery segments were assessable (90%). For the detection of stenoses of more than 50% and more than 75% per segment, 64- MDCT showed a sensitivity of 82% and 86%, respectively. Per segment, specificity and NPV were as high as 95% and 97%, respectively.

As emphasized in Schuijf et al.,⁽¹⁴⁾ meta-analysis, the available MSCT studies have been performed in patients with known CAD or a high likelihood of CAD; in particular, pooling of 24 MSCT studies revealed a prevalence of significant stenoses on MSCT and invasive angiography of 65%. Pooled data from six 64-slice MSCT studies showed a sensitivity of 96% and a specificity of 92% to detect or exclude significant CAD.⁽¹⁴⁾

The current study was performed in patients with predominantly intermediate likelihood of CAD, yet the agreement between MSCT and invasive angiography remains excellent. All patients with normal MSCT had normal coronary arteries on invasive angiography, and all patients with obstructive or nonobstructive CAD on MSCT had CAD on invasive angiography.

64-MDCT coronary angiography provides a significantly increased spatial and temporal resolution compared with earlier MDCT systems. In a clinical setting, this technique may hold great promise for the reliable diagnosis or exclusion of significant CAD on a per patient basis and could give CTA an important role in the stratification of patients with both known and suspected CAD.⁽¹³⁾

In the case of multi–detector row CT, the most effective measure to improve existing platforms is enhancement of temporal resolution to enable motionfree and robust coronary imaging, especially for patients with a moderate or high heart rate. It is to be expected that, for a limited time, further improvements in scanner performance will be pursued by adding additional detector rows. This will further reduce scanning times and benefit general CT applications but will not improve the temporal or spatial resolution of CT acquisitions in the heart. Increased temporal resolution can be achieved by means of segmented reconstruction techniques in which two or more segments from consecutive heart cycles are used for reconstruction.⁽¹⁵⁾

5. Conclusion

The use of noninvasive 64- slice CT coronary angiography as a vascular imaging technique can be performed rapidly and safely for the assessment of many different pathologies involving coronary arteries with a high diagnostic accuracy.

References

- [1]. **MA.Khan, MJ.Hashim, H.Mustafa, et al.** Global Epidemiology of Ischemic Heart Disease: Results from the Global Burden of Disease Study. *Cureus*.vol.12(7),pp.e9349,2020.
- [2]. **NA.Ramjattan, V.Lala, O.Kousa, et al.** Coronary CT Angiography. [Updated 2022 Jan 21]. In: StatPearls [Internet]. Treasure Island (FL): StatPearls Publishing,2022.
- [3]. **A.Sabarudin, & Z.Sun,** Coronary CT angiography: Diagnostic value and clinical challenges. *World journal of cardiology*.vol. 5(12),pp.473–483,2013.
- [4]. **SA.Kumar, Vadanika Venu, Bulabai Karpagam, Vinayagam Shanmugam, Kodithandalam Chakrapani Saravanan** Role of 64- Slice MDCT-Coronary Angiography in the Evaluation of Various Coronary Artery Pathologies: Comparison with Catheter Coronary Angiography.vol.5(2),pp.30-34,2016.
- [5]. **B.Hennessey, R.Vera-Urquiza, H.Mejía-Rentería, N.Gonzalo, & J.Escaned,** Contemporary use of coronary computed tomography angiography in the planning of percutaneous coronary intervention. *The International Journal of Cardiovascular Imaging*,pp.1-19,2020.
- [6]. **S.Leschka, Hatem Alkadhi, André Plass, Lotus Desbiolles, Jürg Grünenfelder, Borut Marincek, Simon Wildermuth,** Accuracy of MSCT coronary angiography with 64-slice technology: first experience, *European Heart Journal*.vol.26, pp.1482–1487,2005.
- [7]. **M.M.E.Rakhawy, N.M.Fouda, N.A.E.G.E.Toukhy, & A.F.A.E.Ftough,** MDCT angiography and coronary catheter angiography in patients with chest pain which is first. *The Egyptian Journal of Radiology and Nuclear Medicine*.vol.49(4),pp.1145-1154,2018.
- [8]. **A.Kuettner, A.F.Kopp, S.Schroeder, T.Rieger, J.Brunn, C.Meisner, & C.D.Claussen,** Diagnostic accuracy of multidetector computed tomography coronary angiography in patients with angiographically proven coronary artery disease. *Journal of the American College of Cardiology*.vol.43(5),pp.831-839,2004.
- [9]. **G.Pundziute, J.D.Schuijf, J.W.Jukema, E.Boersma, A.de Roos, E.E.van der Wall, & J. J. Bax,** Prognostic value of multislice computed tomography coronary angiography in patients with known or suspected coronary artery disease. *Journal of the American College of Cardiology*.vol.49(1),pp.62-70,2007.
- [10]. **JW.Kang, JB.Seo, EJ.Chae, YM.Jang, KH.Do, JS.Lee, JW.Song, et al.** Coronary artery anomalies: classification and electrocardiogram-gated multidetector computed tomographic findings. *Seminars in Ultrasound, CT and MRI* .vol. 29,pp.182-194,2008.
- [11]. **SY.Kim, JB.Seo, Do.KH, et al,** Coronary artery anomalies: classification and ECG-gated multi-detector row CT findings with angiographic correlation. *Radiographics*.vol.26,pp.317–34,2006.
- [12]. **JD.Dodd, M.Ferencik, RR.Liberthson, RC.Cury, U.Hoffmann, TJ.Brady, S.Abbara,** Congenital anomalies of coronary artery origin in adults: 64-MDCT appearance. *AJR Am J Roentgenol*.vol.188(2),pp.W138-46,2007.
- [13]. **K.Nikolaou, A.Knez, C.Rist, B.J.Wintersperger, A.Leber, T.Johnson, & C.R.Becker,** Accuracy of 64-MDCT in the diagnosis of ischemic heart disease. *American Journal of Roentgenology*.vol.187(1),pp.111-117,2006.
- [14]. **JD.Schuijf, JJ.Bax, LJ.Shaw, et al.** Meta-analysis of comparative diagnostic performance of magnetic resonance imaging and multislice computed tomography for noninvasive coronary angiography. *Am Heart J*.vol.151,pp.404–11,2006.
- [15]. **N. R.Mollet, F.Cademartiri, K.Nieman, F.Saia, P.A.Lemos, E.P.McFadden, & P.J.de Feyter,** Multislice spiral computed tomography coronary angiography in patients with stable angina pectoris. *Journal of the American College of Cardiology*.vol.43(12),pp.2265-2270,2004.