

## Prognostic value of coronary CT angiography for the Prediction of adverse outcomes

M.A.Nasser, A.y.Nammour, O.S.Arafa and A.I.Attia

Cardiovascular medicine, Dept., Faculty of Medicine, Benha Univ., Benha, Egypt

E-mail:

### Abstract

Historically Atherosclerosis and its complications are the leading cause of death in modern countries. In coronary angiography, multislice CT coronary angiography is utilised to investigate the role of plaque characterization and vessel wall analysis in positively reformed lesions and its predictors of 180-day cardiovascular clinical events. Methods: Our research focused on 55 patients who had been referred to the International Cardio Scan Center for Multi Slice CT CA in line with the Society of Cardiovascular Computed Tomography requirements for appropriateness in their specific circumstance. Single vascular disease and lesions with positive arterial remodelling were selected for further examination. A single lesion was chosen for each patient, whether it was the loneliest or the most extensive. Renovated plaque region has a 32.7311.04 percent higher percentage of low attenuation plaque compared to the reference site. According to the research, the remodelling site had a larger percentage of the medium attenuation plaque (62.769.24 percent compared to 50.0414.53 percent) than the reference segment. For quantitative plaque evaluation and the assessment of positive remodelling, MDCT is an excellent noninvasive alternative to IVUS since it includes morphological characteristics, the degree of vessel wall remodelling, the presence of calcification and the attenuation properties of plaque itself.

**Key words:** Coronary artery disease, Coronary angiography, CT scan, Test results.

### 1. Introduction

The Atherosclerosis and its complications are the leading cause of death in modern societies. A increasing body of data suggests that some of these coronary hot spots are activated and burst, leading in acute events, whereas other hot spots are connected to quiet disease progression [1].

Plaque lipid content was shown to be positively associated with remodelling of coronary atherosclerotic lesions, as was a decrease in plaque attenuation on CT.

To detect plaques that are at danger of rupture and other detrimental outcomes, CT imaging may be a helpful technique [2].

It was determined that coronary artery remodelling was characterised by an increase or decrease in vessel diameter in comparison to a normal-appearing vascular segment that was located near the lesion (reference segment). It is termed positive remodelling on MDCT if the plaque site is at least 10% larger in diameter than a reference segment [3].

A large plaque and a necrotic core are thought to be the primary factors influencing plaque susceptibility, according to the literature. The lumen is spared when the vessel undergoes a positive or outward remodelling. As a result, angiographic luminal assessment is not well correlated with the incidence of acute coronary syndromes when the lumen infiltration is restricted. Lesions with necrosis, large necrotic cores, lipids in the core, macrophage inflammation, and calcium deposits are more likely to undergo vascular remodelling. However, stable plaques compress instead of expanding. Due to its rapid growth, the vessel is an ideal target for structural imaging [3].

Plaque progression and reversal are both associated with arterial expansion (positive remodelling) and shrinkage (negative remodelling). More than a few studies have shown that the majority of acute coronary syndromes are initiated by fast changes in moderately stenotic lesions, which are often seen in regions of positive remodelling. As

a result, the identification of atherosclerotic lesions that are only mildly stenosed but nonetheless vulnerable may be a stronger indicator of coronary risk than the assessment of luminal stenosis itself [1].

Thine Cap fibroatheroma lesions were more common in lesions that were undergoing positive remodelling than in lesions that were not. Necrotic core and TCFA are more common in lesions with positive CTA remodelling on VH IVUS images, suggesting an increased susceptibility to plaque. When it comes to plaque susceptibility, the CTA evaluation of remodelling may be a relevant marker to look for [4].

Mulidetector CT was used to effectively reconstruct lesions, and this study sought to assess the plaque and artery wall morphology and predictability of 180-day cardiovascular events.

### 2. Patients and methods

Between 220 individuals who had been sent to the International Cardio Scan Center for Multi Slice CT CA in line with SCCT criteria for appropriateness were evaluated between January 2020 and January 2021.

Only those patients having Single vascular disease and lesions that exhibited positive arterial remodelling were selected for further investigation. A single lesion was chosen for each patient, whether it was the only one or the most extensive.

#### Exclusionary conditions:

Pregnant women are included in this category.

Patients with renal impairment.

When a patient's hemodynamic status is unstable.

Contrast-sensitive individuals.

• Patients having a noticeable irregular heartbeat.

Any prior PCI or CABG patients.

• Lesions creating a stenosis of greater than 70%.

Detailed history collection, clinical evaluation, and laboratory testing were performed on each patient.

2.2MDCT

MDCT was performed using a 64-slice CT scanner (Aquillion 64, Toshiba Medical, Tokyo, Japan). The

patient was administered 50mL of contrast agent (Ultravist) intravenously at a rate of four millilitres per second. Upon reaching a preset threshold of 100 Hounsfield units (HU) in the ascending coronary artery, computed tomography (CT) data and an electrocardiogram (ECG) were recorded. With a collimation of 640.5mm and an imaging time of 400ms, the volume data set was collected in spiral mode using 120 kV and 400mA tube energies for coronary artery imaging. While the photos were being shot, an ECG was being continuously recorded to guarantee the subject's safety. The raw scan data of all individuals was segmented and reconstructed using a segmentation technique. Reconstructed MDCT angiogram images were processed utilising computer software installed on the machine (Vitrea, Tokyo, Japan).

coronary artery calcium deposits (CAC)

It was possible to find out the blood calcium level using a scoring application on a computer in Tokyo, Japan (Vitrea). On CT scans, CAC was identified by the presence of more than two consecutive pixels with a HU value more than 130. Each lesion's CAC score was calculated using the Agatston method. There were two-millimeter collimation widths and rotation rates of zero to four revolutions per second and currents of 300 milliamperes used to find the heart.

The plaques were examined in detail.

This was done following a comprehensive visual inspection of the volume-rendered images, which revealed an overall structure of the coronary artery lumen, of the coronary artery plaques.

Each patient was given a plaque with a diameter of at least 2 millimetres that induced less than 70% stenosis.

Plaques and the heart's structure may be found with this method, which employs magnetic resonance imaging.

Cardiovascular reshaping was assessed using cross-sectional imaging techniques like IVUS. The Remodeling Index was computed based on the lesion-to-reference segment vascular area ratio.

RI is higher than 1.05. Used to signify good change.

The collected images were saved on a PC that was not connected to the Internet (Toshiba Vitrea Medical Systems)

The results of the CT scan will be analysed in the post-processing phase.

An orthogonal serial multiplanar reconstruction was created for each coronary artery segment using a one-millimeter thick slice.

The cross sectional vascular area in the reference segment without apparent plaque proximal to the coronary lesion was measured.

Using an automated software application for vessel analysis, multiple measurements were acquired at the location of highest arterial remodelling and compared to a reference segment. Vitrea and Toshiba Medical make vessel analyzers.

\* The Lumen region.                      \*The vessel's surface area.  
wall's surface

Percentage of the wall/lumen surface area.

A total of five Plaque Burden %.

Calculations of attenuation and calcification, surface area percentages, and the plaque mean density were performed for each individual plaque to estimate the relative component attenuation (low attenuation, medium attenuation).

According to the following Color Coded Spectrum and HU attenuation, the Software categorised each plaque component into one of three groups.

An attenuation range between 0 and 1 for a low attenuation plaque (-100:49 HU coded with Red color)

This medium attenuation plaque shows attenuation levels from (50:149 HU) in blue.

Plaque 3: High attenuation plaque has an attenuation range (150:1300 HU) characterised by the yellow colour of calcium.

Cross-sectional vessel areas were used to assess the remodelling index (RI= Affected segment surface area/Reference segment surface area).

SCCT and the CAD RADS Reporting System found that all of the lesions had a stenosis severity of minor, mild, or severe.

Six months following the index lesion, the patient was re-evaluated for potential cardiovascular events, including ACS, heart failure, myocardial infarction, coronary angiography, and PCI.

Statistical analysis

Once the data had been collected, edited, coded, and entered into IBM SPSS version 20, the following procedures were followed: Qualitative data was represented by numbers and percentages, but quantitative data was represented by standard deviations and ranges... It was used to compare qualitative data from two groups by using the chi-square test.

A parametric distribution and quantitative data were utilised to compare two independent groups using the Independent t-test. The ROC curve's specificity and positive predictive value were used to identify the optimal cutoff point. The margin of error was set at 5% by setting the confidence interval to 95 percent. The following is an explanation of the p-relevance value's in this case: First, second, and third are the most important. statistically insignificant; somewhat important; and very important (P 0.01).

### 3. Results

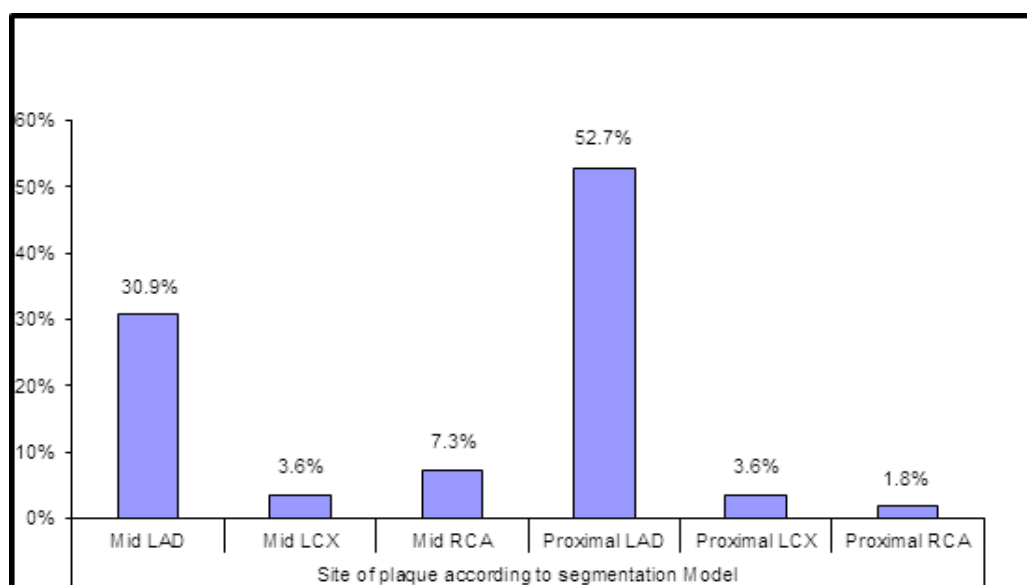
The International Cardio Scan Site for CCTA received 220 patients between January 2020 and January 2021 for a prospective single centre research. There were 156 men in the study (70.9 percent ). It was 55.62 7.78 years old on average. It was found that 96 of the patients had previously been admitted to the CCU because to ACS. 32 individuals had stable coronary artery disease, whereas 56 patients experienced unusual chest discomfort, 36 of whom had dyspnea, at their first presentation. Patients with an LV systolic function of 59.33 5.62 percent had normal ejection fractions, the study found. Dyslipidemia was detected in the majority of the 148 patients who tested positive for various coronary heart disease risk factors (67.3 percent ). As indicated in the table below, diabetes was discovered in 116 patients (52.7% of the total sample) and hypertension in 124 patients (56.4%), respectively. a table illustrating.

**Table (1)** Information on a patient's age, gender, risk factors, and clinical presentation.

		No. = 200
a person's chronological age (years)		55.55±3.1
Males		56
BMI \sSmokers		58.25±2.4
Hypertensive \sDiabetics		116 (5.71%)
a person's chronological age (years)		124 (2.32%)
Males		120 (49.1%)
<b>DM type</b>	DM type I	18 (12.3%)
	DM type II	99 (58.7%)
<b>Duration of DM (years)</b>		15.87 ± 5.20
<b>Dyslipidemia</b>		156 (61.3%)
<b>Family history</b>		40 (11.7 %)
<b>Initial presentation</b>	ACS	96 (99.6%)
	Dyspnea	52 (27.5%)
	Stable coronary ischemia	21 (17.4%)
	Atypical Heart ache	5 (13.5%)
<b>EF (%)</b>		53.31 ± 4.67

**Plaque identification using computed tomography (CT) imaging**

In this investigation, 24 of the 220 lesions were determined to have moderate stenosis, with 52.7 percent of the lesions identified in the proximal LAD and 30.9 percent found in the middle of the LAD (Figure 1). Compared to the proximal RCA, the RCA remodelling lesions were observed more often in the middle segment (7.3 percent) (1.8 percent). Neither the frequency of proximal nor mid-LCX lesions differed (Figure 1).

**Fig. (1)** Site of plaque according to segmentation model.

Each plaque underwent semi-automated computations to identify three distinct types of plaque components using a colour code similar to that used by IVUS. Plaque with a mean density between -100 and 49 HU was recognised by the red-coded low attenuation component.

Plaques with a mean density of between 50 and 149 HU were detected by the blue-coded medium attenuation plaque component. Those whose mean plaque density falls

between 150 and 1300 HU have a high attenuation component, which is shown by the colour yellow. This indicates that the component is mostly calcium.

CT scans were performed on the reference and remodelling parts in turn. The results are shown below. (table2) There were 1.41 0.25 calculated remodelling indices in the sample.

Table (2) at both the reference and remodelling segments, CT measurements were taken.

	Variable	Reference segment	Remodeling segment
Area (mm <sup>2</sup> )	Plaque for the whole of the vessel walls	124 (2.4%)	55.55±7.78
	Plaque of different attenuation levels: Low, medium, and high	120 (49.7%)	56 (55.9%)
%	Lumen region on the wall	18 (12.3%)	58.25±2.49
	Inflict a tax	<b>Median 2 (2 - 3)</b>	116 (5.7%)
%	Plaque with low amplification	<b>Median 5 (4 - 6)</b> 2 - 51	124 (2.4%)
	Plaque region with medium attenuation	<b>Median 0 (0 -1)</b> 0 - 6	120 (49.7%)
%	There are three levels of attenuation plaque: high, medium, and low.	58.25±2.49	18 (12.3%)
	Plaque with high amplification	116 (5.7%)	99 (58.7%)
Mean Denisty(HU)	Total ca score for the plaque	124 (2.4%)	15.39 ± 5.20
	Plaque for the whole of the vessel walls	120 (49.7%)	156 (61.3%)
Mean Denisty(HU)	Plaque of different attenuation levels: Low, medium, and high	<b>Median 3 (0 - 10)</b> 0 - 32	40 (11.2 %)
	Lumen region on the wall	<b>Median 18 (13 -26)</b> 0 - 30	96 (99.6%)
CA Score (Agatston method)	Inflict a tax	92.04 ± 9.79	52 (27.5%)
	Plaque with low amplification	<b>Median 158(125- 14)</b> 0 - 230	21 (17.4%)
CA Score (Agatston method)	Plaque region with medium attenuation	<b>Median 0 (0 - 0)</b> 0 - 74	5 (13.5%)
	There are three levels of attenuation plaque: high, medium, and low.	<b>Median 0 (0 - 0)</b> 0 - 877	55.25±1.78

**Aftercare**

A 180-day follow-up was carried out in order to evaluate the risk of cardiovascular events. One hundred patients were found to have ACS, CA, 40 CA patients, and PCI all associated to the index lesion, for a total of one hundred patients. There were no heart attacks or deaths throughout the study's follow-up period. Patients who have had diabetes for more than six months are more likely to have complications, according to Table 3.

**The Remodeling Index (RI)**

Some coronary artery disease risk variables were shown to be unrelated to the location of remodelled lesions. An overhaul of both its lumen and its vessels.

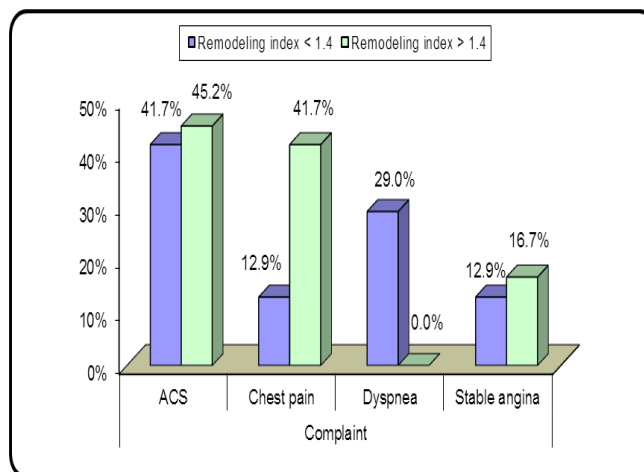


Fig. (2) Relation between patient complaint and remodeling index.

#### 4. Discussion

Atherosclerotic lesions may cause changes in artery diameter, which may be explained by coronary artery remodelling. Lumen size is maintained despite plaque buildup, since early lesions undergo positive remodelling (expansion). Contrary to the existence of calcified plaque, negative remodelling (shrinking) results in luminal stenosis [1].

Atherosclerotic lesions with the greatest extent were discovered in this study. It was determined that the most proximal portion with no visible plaque was the best reference point.

We discovered that vascular remodelling in both sexes was favourable, with larger vessels and better outer form in the vessel wall. Patients with unstable angina were more likely to have lesions with a higher remodelling index.

The remodelling site's Low Attenuation Plaque area was 32.7311.04 percent greater than the reference segment's, based on the mean remodelling index.

The remodelling site had a lower percentage of the mid-attenuation plaque component (62.769.24 percent) than the reference segment (50.0414.53 percent).

All of the patients had normal LV systolic function. 67.3% of patients had dyslipidemia, while diabetes was present in 52.7% of those who had it, making it the most frequent risk factor.

40 to 50 percent luminal stenosis was seen in the majority of lesions investigated throughout this research project.

A substantial connection was seen between poor plaque attenuation and lesions with a high remodelling index. Remodeling was observed to be mostly confined to more proximal parts of the LAD (83.6 percent of the time).

Schmid et al. [2] found that positive remodelling of coronary atherosclerotic lesions corresponds to lower CT attenuation of plaques, which had previously been linked to lipid-rich plaques. Our results were similar to theirs. CCTA is more likely to be used to identify sensitive plaque and future occurrences since these features imply a higher risk.

To put it another way, the vessel area was 26.4910.63 mm<sup>2</sup>, the wall area was 17.496.92 mm<sup>2</sup>, and the plaque load was 66% and 17.226.64 mm<sup>2</sup>, respectively [2].

There were 18.936.98 mm in diameter, an 84.003 mm wall area, 44.675 percent plaque load, and 8.443.28 mm<sup>2</sup> of plaque in the vessel.

The bigger mean reference cross-sectional vessel area of 0.22 0.09 cm<sup>2</sup> and the smaller lesion cross-sectional vessel area of 0.25 0.08 cm<sup>2</sup> may be to blame. According to the authors (Schmid et al.

If there are differences in size, it might be because to lesions in the vessel's middle. A total of 47 lesions (42 percent) were found in the proximal segments, whereas 65 lesions (65 percent) were found in the mid coronary segment (58 percent). On the other hand, we paid more attention to the lesions that were closest to our hearts.

In both investigations, there was no association between the remodelling score and age or gender.

There was a mean CT attenuation of 5925HU in 72 lesions with positive remodelling, according to Schmid

and associates' data; this ranged between 26–109HU [2]. These lesions were found to be of 91 20 HU CT density, the median value of which was 89, while the range was 43–132.

There was no difference in CT attenuation amplitudes for any plaque component between lesions with positive remodelling and high RRI and those without.

Sung et al. [5] conducted research on the subject. By analysing the plaque type and positive remodelling and patchy cavitation or napkin rings, MDCT had an extra predictive value in 1418 cerebral stroke patients.

Motoyama et al. [3], who examined the CT features of coronary lesions in ACS, found similar results. Researchers used CT plaque measures such as vascular remodelling and the consistency of non-calcified plaque to compare the two groups of patients with coronary artery disease (CAD) and stable angina pectoris (SAP).

Research found that positive remodelling, NCP below 30 Hue, and patches of calcium were more common in ACS lesions (87 percent vs. 12 percent, NCP less than 30 Hue, and spotty calcium, respectively). Having all three (positive remodelling, NCP 30 HU, and patchy calcification) showed a substantial positive predictive value; on the other hand, not having all three had a significant negative predictive value.

Retrospective results show that individuals with coronary plaques showing positive vascular remodelling and significant low attenuation regions on CCTA are more likely to suffer from acute coronary syndromes (22.2 percent versus 0.5 percent).

Patients with ACS, CA, and 10 patients with ACS who received medical therapy, six of whom underwent PCI linked to the index lesion, were included in our study after 90 days of follow-up. We also included 25 healthy patients. During the time of follow-up, no one died as a result of a fatal myocardial infarction.

It was shown that lesions with a longer history of diabetes were more likely to have a visual stenosis of more than 60%.

Each IVUS-like plaque was categorised into three unique colour codes using automated techniques. Neither the volume of plaque nor the area of the plaque was discernible. Researchers Nadjiri et al. [6] and Tesche et al. [7], as well as ourselves, discovered a relationship between high-risk plaque characteristics including positive remodelling and an insufficient attenuation region and future cardiovascular clinical events.

Clinical recurrences were shown to be closely linked to plaque load and wall/lumen area percentage in areas with positive remodelling.

Nadjiri et al. observed that coronary CT angiography quantitative plaque evaluation has additional prognostic value. Their 1168 patients with probable coronary artery disease were studied segment-by-segment for calcified, non-calcified, or partially calcified plaques (CAD). Semi-automated plaque analysis was used to determine the low attenuation plaque volume (density 30 HU), total non-calcified plaque volume (TNCPV, 150 HU), and remodelling index (SAP). After a coronary CT scan that lasted more than 90 days, the primary outcome of the trial

was MACE, a tally of cardiac mortality, myocardial infarction, and coronary revascularization. After 5.7 years of follow-up, MACE was found in 46 participants (3.9 percent). MACE was responsible for all of the plaque features. LAPV was shown to be the most significant relationship.

Quantitative coronary CT angiography-derived indicators were employed in a research by Tesche et al. to predict the likelihood of a cardiac event.

Kröner et al. [4] used computed tomography and virtual histology intravascular ultrasonography to discover a relationship between positive CT remodelling and the existence of susceptible plaque features (VH-IVUS). CT and VH-IVUS scans were performed on 45 individuals. The positive remodelling index was calculated using CTA and RI 31.0. VH IVUS scans demonstrated the presence of thin-capped fibro atheroma as a sign of plaque susceptibility (TCFA). A total of 97 plaques were analysed, with 37 indicating signs of CTA change. Lesions with positive remodelling were more vulnerable to plaque formation than lesions without positive remodelling. More TCFA plaque and necrotic cores were seen when tumours were negatively redesigned.

This was corroborated by VHIVUS imaging, which demonstrated that lesions with CTA-detected positive remodelling had a greater probability of plaque formation. The degree of remodelling observed on an MRI might be a predictor of plaque susceptibility. CTA.

## 5. Limitations

The tiny population size is seen as a disadvantage.

Coronary angiography was unable to assess the severity of the coronary lesion.

When compared to other techniques, like IVUS, virtual histology stands to gain.

Having a brief follow-up time suggested for future cardiovascular occurrences.

On a CT scan, it's tough to find a healthy reference region that's devoid of any discernible abnormalities.

For the measurement of cross sectional vessel area, it is yet to be determined which artery wall construction truly contributes.

Extensive calcification makes it more difficult to get precise vascular measurements.

## References

- [1] P Schoenhagen, M Barreto, SS Halliburton. Quantitative plaque characterization with coronary CT angiography (CTA). *Int J Cardiovasc Imaging*,VOL.24(3),VOL.313–6,2008.
- [2] M Schmid, T Pflederer, I-K Jang, K Ropers Sei, WG.Daniel Relationship between degree of remodeling and CT attenuation of plaque in coronary atherosclerotic lesions: an in-vivo analysis by multi-detector computed tomography. *Atherosclerosis*,vol.197(1),PP.457–64,2008.
- [3] S Motoyama, T Kondo, M Sarai, A Sugiura, H Harigaya, T Sato, Multislice computed tomographic characteristics of coronary lesions in acute coronary syndromes. *J Am Coll Cardiol* , vol.50(4),pp.319–26,2007.
- [4] ESJ Kröner, JE van Velzen, Boogers MJ, Siebelink H-MJ, Schalij MJ, Kroft LJ, Positive remodeling on coronary computed tomography as a marker for plaque vulnerability on virtual histology intravascular ultrasound. *Am J Cardiol*,vol.107(12),pp.1725–9,2011.
- [5] T Pflederer, M Marwan, T Schepis, D Ropers, M Seltmann, G Muschiol, Characterization of culprit lesions in acute coronary syndromes using coronary dual-source CT angiography. *Atherosclerosis* ,vol.211(2),pp.437–442010.
- [6] J Nadjiri, C Hausleiter, A Jähnichen, E Will, Hendrich, S Martinoff, Incremental prognostic value of quantitative plaque assessment in coronary CT angiography during 5 years of follow up. *J Cardiovasc Comput Tomogr*,vol.10(2),pp.97–104 , 2016.
- [7] C Tesche, F Plank, CN De Cecco, TM MH Duguay, A Albrecht, Varga-Szemes,. Prognostic implications of coronary CT angiography-derived quantitative markers for the prediction of major adverse cardiac events. *J Cardiovasc Comput Tomogr* ,vol.10(6),pp.458–65,2016.