

Outcome of surgical evacuation of spontaneous supratentorial Intra cerebral hemorrhage (ICH)

Mansour Hamada, H.M.Hammam, A.M.Omar, Mohamed Elhawary and Shawky A. Elmeleigy

Neurosurgery, Dept., Faculty of Medicine, Benha Univ., Benha, Egypt

E-mail: Mansour.Imam21@fmed.bu.edu.eg

Abstract

Background: Spontaneous, nontraumatic intracerebral hemorrhage (ICH) remains a significant cause of morbidity and mortality throughout the world. Although ICH has traditionally lagged behind ischemic stroke and aneurysmal subarachnoid hemorrhage in terms of evidence from clinical trials to guide management, the past decade has seen a dramatic increase in studies of ICH intervention. The aim of the present study was to evaluate the survival and functional outcome after surgical evacuation of spontaneous supratentorial intra cerebral hemorrhage and factors affecting prognosis. **Methods:** This is a prospective study for 50 consecutive patients admitted to neurosurgery department in Benha university Hospital suffering from spontaneous intra cerebral hemorrhage (ICH) in ER where examination was done including the general examination, neurological and other systems. Initial CT brain scan was done on admission by evaluation of size of hematoma, site, midline shift, presence of intra ventricular extension. **Results:** According to Mortality rate, 10 (20%) patients died within average of 7.5 days after surgery ranged between 0 to 13 days. their initial GCS before surgery was 5 in four cases and 6 in 6 cases which worsen after surgery. Survived cases needed average of 2.92 ± 1.03 days to be fully conscious ranged between 2 to 5 days. mRS distribution in all studied group after 6 months of surgery was varied between 0 to 6 as 0 grade means no residual symptoms in 2 (4%) patient while 4 (8%) patients showed grade 1 no significant disability, 10 (20%) patients showed grade 2 slight disability, 20 (40%) patients showed grade 3 moderate disability and 10 (20%) showed grade 6 which means dead cases. There was statistically significant difference between Mean GCS before and after surgery ($p < .0001$) as it was 9.04 and improved to 11.56 before leaving hospital. The mean mRS after surgery and before leaving the hospital was 3.72 ± 0.91 ranged between 1 to 5 while after 6 months the mean improved to 3.2 after 6 months with a statistically significant difference ($p = 0.0013$). **Conclusion:** Craniotomy and evacuation of spontaneous supratentorial ICH in patients with good premorbid status and moderate to good GCS even with big sized hematoma (more than 50 ml) have better long-term functional outcome. A combination of surgery and neurocritical care can result in favorable clinical outcome, regardless of ICH size or location.

Key words: surgical evacuation - Outcome - spontaneous supratentorial Intra cerebral hemorrhage - ICH

1. Introduction

Spontaneous intracerebral hemorrhage (ICH) is defined as hemorrhage in the brain in the absence of immediate trauma. It can be divided into primary and secondary types.^[1]

Primary ICH occurs in the absence of a structural disease process and it accounts for 70–80% of cases and are caused by either chronic hypertension, which accounts for more than 50% of cases or amyloid angiopathy.^[2]

Secondary intracerebral hemorrhage occurs in a minority of patients in association with vascular abnormalities (such as arteriovenous malformations and aneurysms), tumors, or impaired coagulation. Although hypertensive intracerebral hemorrhage remains the most common form of intracerebral hemorrhage, underlying vascular abnormalities should always be considered in appropriate circumstances because of the high risk of recurrent hemorrhage and available treatment options.^[3]

Spontaneous intracerebral hemorrhages (ICH) constitute 9–27% of all strokes worldwide, and are significant causes of morbidity and mortality with a 30-day mortality of about 35–45%.^[4]

Symptomatic hematomas can be grouped according to site to as (1) cortical, involving the cortex (2) subcortical involving deep white matter regions, (3) basal ganglionic/thalamic,^[5]

Computed tomography (CT) scan of the brain has a sensitivity and specificity that approaches 100% for acute ICH. CT may also show basic characteristics of the hematoma, such as: hematoma location, extension to the ventricular system, presence of surrounding edema, development of mass effect and midline shift. A quick estimation of the hematoma volume can be rapidly performed in the ED with the validated ABC/2 technique.^[6]

The management of ICH is controversial. Studies show that those who suffer ICH have a 30-day mortality rate of 35–44% and a 6-month mortality rate approaching 50%. The medical management includes control of blood pressure which is the most important factor in determining the rapid extension of ICH.^[7]

Medical control of intracranial pressure (ICP) with the use of osmotic diuretics; mannitol, which safely and effectively lowers the ICP. Other methods as hypocarbia and sedation with neuromuscular paralysis, all aim at decreasing the ICP [1]. The use of steroids is controversial.^[8]

Surgical evacuation of ICH helps to reduce nervous tissue damage by relieving local ischemia or removal of noxious chemicals from degraded blood along with relieving raised ICP. Nevertheless, responses to surgery do not seem to be homogeneous. For example, early surgery may be beneficial for large, surgically accessible hematomas (lobar) exerting a mass effect;

whereas deep seated hematoma with long surgical approach that cross eloquent brain areas probably do not.^[9]

Spontaneous ICH is a treatable condition provided that the patients receive appropriate care from trained staff to deal with such cases. The best candidates for ICH evacuation are those with hematoma volume 30–60 ml and GCS more than 10.^[10]

While patients with poor GCS at presentation and pupillary inequality suggests greater primary brain injury and herniation leading to prolonged ventilator support. Most of these patients end up in vegetative state.^[11]

The aim of this work was to evaluate the survival and functional outcome after surgical evacuation of spontaneous supratentorial intra cerebral hemorrhage and factors affecting prognosis.

2. Patients and Methods

This is a prospective study for 50 consecutive patients admitted to neurosurgery department in Benha university Hospital suffering from spontaneous supratentorial intra cerebral hemorrhage (ICH) in ER where examination was done including the general examination, neurological and other systems. Initial CT brain scan was done on admission by evaluation of size of hematoma, site, midline shift, presence of intra ventricular extension.

Indications of surgery was done regarding hematoma size, site, midline shift, clinical condition of the patient and other comorbidities as following

Inclusion criteria:

- All operated cases of spontaneous supratentorial ICH.

Exclusion criteria:

- age less than 18 years old
- posterior fossa hematoma
- traumatic intra cerebral hemorrhage
- Associated diffuse subarachnoid hemorrhage
- GCS less than 5
- Hematoma volume less than 50 ml

Preoperative assessment

All patients underwent complete general and neurological examination. Presenting symptoms/condition, GCS, sex as regards male to female ratio, age, blood pressure, and blood glucose level were observed. Associated medical history was also evaluated.

Neuroradiological assessment

- Preoperative CT scan brain was done to all the cases
- The hematoma volume was calculated using the modified ellipsoid method: $(A \times B \times C) / 2$, where A is the largest diameter of the hematoma on axial CT scan slice (cm); B is the diameter perpendicular to A on the same slice; and C is the thickness of the hematoma on CT (cm), also counted as the number of axial cuts on CT multiplied by slice thickness (cm) (excluding the highest and lowest cuts visualizing the ICH).

Laboratory assessment

Routine preoperative and postoperative laboratory investigations were done: complete blood count, bleeding profile (prothrombin time, prothrombin

concentration (PC), international normalized ratio, and partial thromboplastin time), liver and kidney function tests (alanine aminotransferase, aspartate aminotransferase, serum urea, serum creatinine), serum sodium, and potassium levels were assessed.

Surgical procedures

All cases were admitted to the neuro-ICU at our trauma and emergency department and given a loading dose of phenytoin and brain dehydrating measures such as mannitol and furosemide. Cases were operated upon within a period of 24 h of presentation.

All the surgeries were conducted by a special sICH treatment team. All the patients received hematoma evacuation. The techniques used were craniotomy.

Patient lies on an operating table and receives general anesthesia. The head is set in a three-pin skull fixation device attached to the operating table, in order to hold the head standing still. Once the anesthesia and positioning are established, skin is prepared, cleaned with an antiseptic solution, and incised typically behind the hairline.

Then, both skin and muscles are dissected and lifted off the skull. Once the bone is exposed, burr holes are built in by a special drill. The burr holes are made to permit the entrance of the craniotome. The craniotomy flap is lifted and removed, uncovering the dura mater. The bone flap is stored to be replaced at the end of the procedure. The dura mater is then opened to expose the brain parenchyma. Surgical retractors are used to open a passage to assess the hematoma.

The hematoma was reached by the shortest approach as possible avoiding further injury to eloquent brain-areas. After smallest possible incision, the cortex is forced apart with self-retaining spatula and the hematoma cavity is localised. Parts of the hematomas are removed with forceps, while paying attention to avoiding new bleeding in margin zones of the hematoma.

After the hematoma is drained, the retractors are removed, the dura mater is closed, and the bone flap is positioned, aligned, and fixed with metal clips. Finally, the skin is sutured

Decompressive craniotomy was conducted if necessary. In some conditions, an extraventricular drainage was conducted before or after the operation. The surgical method was decided by the surgeons preoperatively. All the craniotomy hematoma evacuation was assisted by operative microscope and followed the principle of minimally invasiveness.

Postoperative treatment

All the patients received standard postoperative medical treatments. The medical treatments included decreasing intracranial pressure, blood pressure control, prevention of complications, and other treatments individually. The mannitol or glycerin fructose was administered with appropriate dose based on the clinical conditions of patients.

Surgical outcome

All cases underwent postoperative general and neurological examination and the outcome of the operated patients was evaluated as regards GCS, residual

neurological deficits, residual hematoma, rebleeding, and GOS.

Outcomes and Data Collection

Patients were followed up for at least 6 months. The primary outcomes assessed were neurological functional status of survivors at 6 months post ictus. The secondary outcomes included: mortality at 30 days, mortality at 6 months post ictus, and complications. The neurological functional status was evaluated by using the Modified Rankin Scale (mRS).

Ethical consideration:

- An informed consent was obtained from parents before enrollment in the study.
- An approval from Research Ethics Committee in Benha Faculty of Medicine was obtained.

Statistical analysis:

Statistical analysis was done and correlate valuable factors that could affect survival and functional outcome

such as age ,sex, hypertension, other comorbidities , pupillary abnormalities , previous stroke , coagulopathy or anticoagulant medications , preoperative GCS and timing of surgery , etc The collected data was presented in tables and suitable graphs and analyzed by (SPSS). Quantitative variables were expressed as mean ± SD, and range. Qualitative variables as frequency and percentage .the level of significance is $p < 0.05$.

3. Results

Regarding risk factors, it was present in 44 (88%) patients. HTN was reported in 26 (52%) patients and diabetes mellitus in 26(52%) patients and 18 (36%) suffered from cardiac disease either IHD or AF or underwent CABAG. 10 (20%) had COVID or postCOVID syndrome while 6(12%) came with history of previous stroke

Table (1) Risk factors in our study

All studied group (N = 50)	
	presented 44 (88%)
	Not presented 6 (12%)
Risk factors	HTN 26 (52%)
	Diabetes mellitus 26 (52%)
	Cardiac patient (IHD/AF/ previous CABAG) 18 (36%)
	COVID /Post COVID Syndrome 10 (20%)
	previous stroke 6(12%)

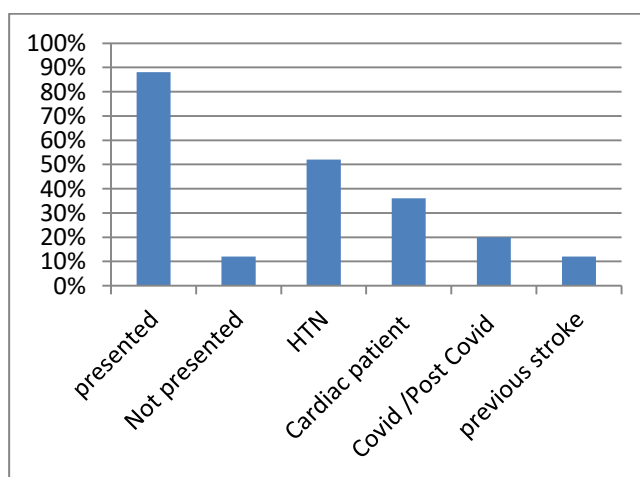


Fig. (1) Risk factors in all studied group

Regarding Anticoagulant therapy **in all studied patients**, 22 (44%) patients took marivan while 14 (28%) patient took only acetylcystiene and 2 patients (4%) took acetylcystiene and clopidogrel

Table (2) Anticoagulant therapy in all studied group.

Anticoagulant therapy	Marivan	22 (44%)
	acetylcystiene	14 (28%)
	Acetylcystiene + clopidogrel	2 (4%)
	No Anticoagulant therapy	12 (24%)

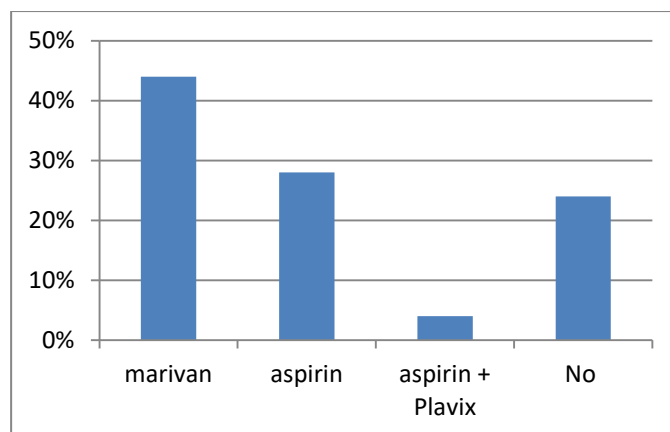


Fig. (2) Anticoagulant therapy in all studied group

The average haematoma size was 68.32 ± 7.70 cc ranged between 55 to 85 cc. regarding Site of hemorrhage, it was Right parietal lobe in 24 (48%) patients, Left parietal lobe in 10 (20%) patients, Right frontal lobe in 6 (12%) patients, Left frontal lobe in 2 (4%) patient and left subcortical with basal ganglia extension in 8 (16%) patients.

Table (3) Size and Site of hemorrhage in all studied group patients

All studied group (N = 50)		
size of haematoma (ml)	mean	68.32
	SD	± 7.70
	Maximum	85
	Minimum	55
Site of haematoma (ml)	Right parietal lobe	24 (48%)
	Left parietal lobe	10 (20%)
	Right frontal lobe	6(12%)
	Left frontal lobe	2(4%)
	Left subcortical with basal ganglia extension	8 (16%)

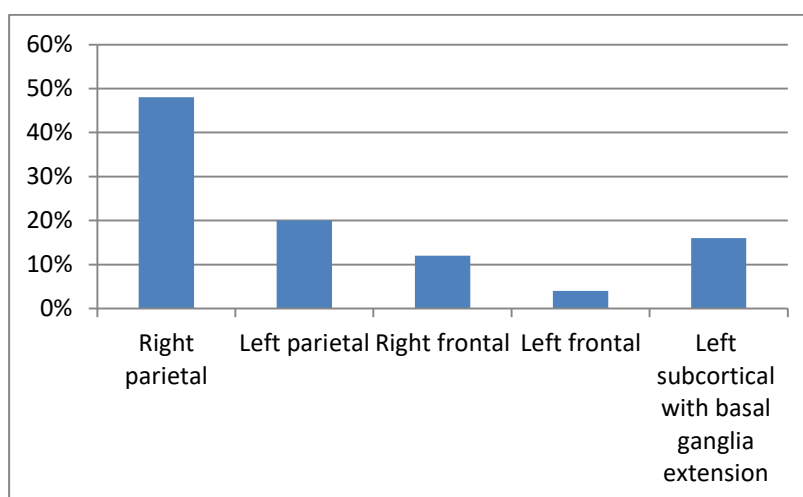


Fig. (3) Site of hemorrhage in all studied patients

The average Initial midline shift was 5.88 ± 1.56 mm ranged between 1 to 8 mm and 8 (16%) patients presented with IVH. The mean of initial GCS before surgery was 9.04 ± 2.01 ranged between 5 to 12 After surgery and before leaving the hospital the mean GCS was 11.56 ± 3.54 ranged between 8 to 14

Table (4) Initial midline shift in all studied patients

All studied group (N = 50)		
Initial midline shift (mm)	Mean	5.88
	SD	± 1.56
	Maximum	8
	Minimum	4

According to Mortality rate, 10 (20%) patient died within average of 7.5 days after surgery ranged between 0 to 13 days . their initial GCS before surgery was 5 in 4 cases and 6 in 6 cases which worsen after surgery. Survived cases needed average of 2.92± 1.03 days to be fully conscious ranged between 2 to 5 days

Table (5) Mortality rate in all studied group

All studied group (N = 50)			
Mortality rate	rate	10 (20%)	
	Mean	7.5	
	SD	± 4.82	
	Maximum	13	
	Minimum	0	
	Post-operative Survival time for dead cases		

Table (6) Postoperative mRS in all studied group

All studied group (N = 50)			
Postoperative mRS	Score	0 no residual symptoms.	0 (0%)
		1 no significant disability	2 (4%)
		2 slight disability	0 (0%)
		3 moderate disability	18 (36%)
		4 Moderate to sever disability	20 (40%)
		5 severe disability	10 (20%)
		6 dead	0
	Mean		3.72
	Median		4
	SD		± 0.91
	Maximum		5
	Minimum		1

mRS distribution in all studied patients after 6 months of surgery was varied between 0 to 6 as 0 grade means no residual symptoms in 2 (4%) patient while 4 (8%) patients showed grade 1 no significant disability, 10(20%) patients showed grade 2 slight disability, 20 (40%) patients showed grade 3 moderate disability and 5 (20%) showed grade 6 which means dead cases

Table (7) 6m Postoperative mRS in all studied group

All studied group (N = 25)			
6m Postoperative mRS	Score	0 no residual symptoms.	2 (4%)
		1 no significant disability	4 (8%)
		2 slight disability	10 (20%)
		3 moderate disability	20 (40%)
		4 Moderate to sever disability	4 (8%)
		5 severe disability	0 (0%)
		6 dead	10 (20%)
	Mean		3.2
	median		3
	SD		± 1.65
	Maximum		6
	Minimum		0

There was statistically significant difference between Mean GCS before and after surgery (p = < .0001) as it was 9.04 and improved to 11.56 before leaving hospital

Table (8) Analysis of outcomes after surgery and 6 months follow-up in all studied group

	Preoperative	postoperative	T test	P value
Mean GCS	9.04	11.56	5.879	< .0001

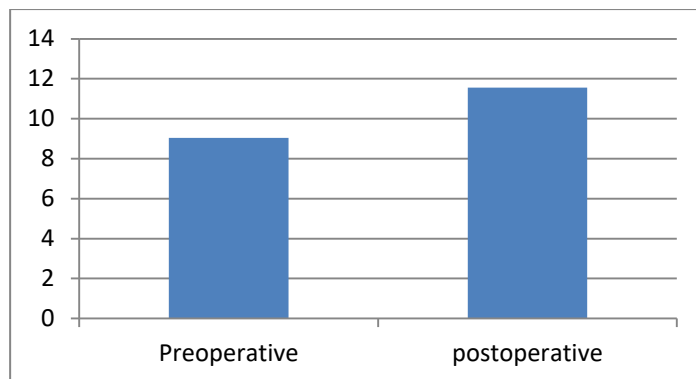


Fig (6) Comparison between GCS postoperative and at 6m after surgery in all studied group

The mean mRS after surgery and before leaving the hospital was 3.72 ± 0.91 ranged between 1 to 5 while after 6 months the mean improved to 3.2 after 6 months with a **statistically significant difference** ($p = 0.0013$)

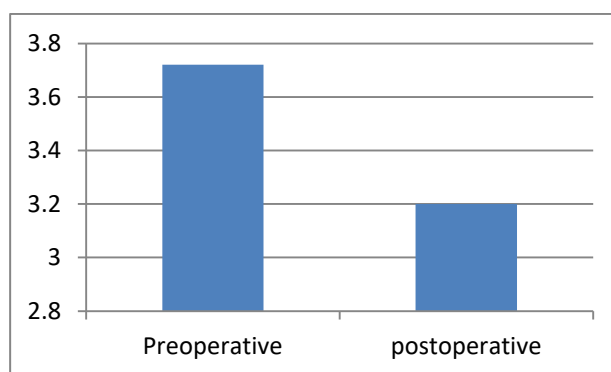


Fig. (7) Comparison between mean mRS postoperative and at 6m after surgery in all studied group

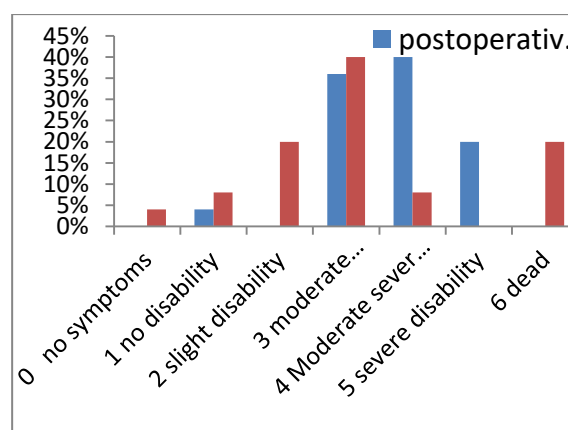


Fig. (8) Comparison between mRS scale postoperative and at 6m after surgery in all studied group

There was a statistically significant correlations between mRS after surgery and initial GCS and also postoperative GCS while no statistically significant correlation between mRS after surgery and (age, hematoma size and midline shift)

Table (10) Correlations between mRS after surgery and other patients properties .

	R	P vlaue
age	0.1637	0.4342
Hematoma size	0.2731	0.1865
midline shift	0.0794	0.7059
intial GCS	0.7099	<0.0001
postop GCS	0.7267	<0.0001

4. Discussion

In the present study, Regarding Anticoagulant therapy in all studied patients , 22 (44%) patients took marivan while 14 (28%) patient took only aspirin and 2 patients (4%) took aspirin + Plavix

In the present study, The average haematoma size was 68.32 ± 7.70 cc ranged between 55 to 85 cc. Regarding Site of hemorrhage, it was Right parietal lobe in 24 (48%) patients , Left parietal lobe in 10 (20%) patients, Right frontal lobe in 6 (12%) patients, Left frontal lobe in 2 (4%) patient and left basal of ganglia in 8 (16%) patients

In contrast to Alkhadrawy et al.,⁽¹⁰⁾ study, he concluded that The basal ganglia is the most common site of ICH, representing 50–60% of spontaneous ICH, and basal ganglia ICH is associated with 50% mortality rate. In our study ICH occurred in basal ganglia in 55%.

In the present study, The average Initial midline shift was 5.88 ± 1.56 mm ranged between 1 to 8 mm and 8 (16%) patients presented with IVH. The mean of initial GCS before surgery was 9.04 ± 2.01 ranged between 5 to 12.

In Lamichhane et al.,⁽¹¹⁾ study, Majority of the patients presented with GCS between 9 and 12 (52.5%) followed by 27.5 % of patients with poor GCS (<8) and remaining 20 % with good GCS (13-15). Hypertension was the most common risk factors among 31 patients with pre-existing co-morbidity. Other risk factors were Diabetes mellitus, COPD, use of anticoagulants, previous infarction, and chronic alcoholism.

In the present study, According to Mortality rate, 10 (20%) patient died within average of 7.5 days after surgery ranged between 0 to 13 days . their initial GCS before surgery was 5 in 4 cases and 6 in 6 cases which worsen after surgery. Survived cases needed average of 2.92 ± 1.03 days to be fully conscious ranged between 2 to 5 days

According to Hessington et al.,⁽¹²⁾ The overall mortality at 30 days and 6 months was 13.0% and 17.9%, respectively, although higher in patients ≥ 65 years old ($p = 0.020$). Thirty-day mortality was 12.9% in patients with deep-seated ICH and 13.1% in lobar ICH ($p = 0.972$)

In the present study, mRS distribution in all studied group after 6 months of surgery was varied between 0 to 6 as 0 grade means no residual symptoms in 2 (4%) patient while 4 (8%) patients showed grade 1 no significant disability, 10 (20%) patients showed grade 2 slight disability, 20 (40%) patients showed grade 3 moderate disability and 10 (20%) showed grade 6 which means dead cases

Median mRS in Hessington et al.,⁽¹²⁾ study was 4.0 for all patients. Of all included patients, 50 (40.7%) had a favorable outcome at follow-up, while 73 (59.3%) had a poor outcome. Among the survivors, 51.0% had a favorable outcome at follow-up and this proportion did not change by ICH location (mRS 0–3, 48.0% in deep ICH vs. 54.1% in lobar ICH; $p = 0.552$). Fortythree survivors (86.0%) with deep-seated ICH and 35 (72.9%) with lobar ICH had focal neurological deficits such as weakness or paralysis in an arm and/or a leg at long-term follow-up, without this difference being statistically significant ($p = 0.136$).

In the present study, The mean mRS after surgery and before leaving the hospital was 3.72 ± 0.91 ranged between 1 to 5 while after 6 months the mean improved to 3.2 after 6 months with a statistically significant difference ($p = 0.0013$).

Of all included patients in Lamichhane et al.,⁽¹¹⁾ study, 20 (50%) had a favorable outcome (mRS 1 to 3) at follow-up, while 20 (50%) had a poor outcome (mRS 4 to 6). Poor/Unfavorable outcome was significantly higher among deep seated hematoma, age>70 years, poor GCS (100ml, patients undergoing decompressive craniectomy, involvement of dominant hemisphere, presence of co-morbidities and pupillary inequality ($p < 0.05$).

In the present study, There was statistically significant difference between Mean GCS before and after surgery ($p < .0001$) as it was 9.04 and improved to 11.56 before leaving hospital.

In Hessington et al.,⁽¹²⁾ et al. study, At discharge, the median mGCS score improved to 6.0 (IQR 5–6; $p = 0.008$), and this improvement was seen both in lobar and deep-seated ICH patients. At 6 months post-surgery, 51 patients (82.3%) in the deep and 50 patients (82.0%) in lobar ICH group were alive. At the final follow-up (range 8– 89 months), 25 patients (20.3%) were dead with no difference between deep and lobar ICH [deep, 12/62 (19.4%); lobar, 13/ 61 (21.3%); $p = 0.965$].

In the present study, There was a strong negative Correlations between mRS after surgery and intial GCS and also postoperative GCS while no statistically significant correlation between mRS after surgery and (age, hematoma size and midline shift).

In the present study, There was a statistically significant correlations between mRS after 6 months of surgery and intial GCS and also postoperative GCS while no statistically significant correlation between mRS after 6 months of surgery and (age, clot size and midline shift).

5. Conclusion

Craniotomy and evacuation of spontaneous supratentorial ICH in patients with good premorbid status and moderate to good GCS even with big sized hematoma (more than 50 ml) have better long-term functional outcome. A combination of surgery and neurocritical care can result in favorable clinical outcome, regardless of ICH size or location.

References

- [1] Edworthy Hseih PC, Awad IA, Getch CC, Bandok BR, Rosenblatt SS, Bayjer HH. Current updates in the perioperative management of intracerebral hemorrhage. *Neurol Clin* 2006; 24:745–764.
- [2] Mayer SA, Rincon F. Treatment of intracerebral hemorrhage. *Lancet Neurol* 2005; 4:662–672
- [3] Qureshi, A. I., Tuhim, S., Broderick, J. P., Batjer, H. H., Hondo, H., & Hanley, D. F. (2001). *Spontaneous Intracerebral Hemorrhage. New England Journal of Medicine, 344(19), 1450–1460.*
- [4] Feigin VL, Lawes CM, Bennett DA, Barker-Collo SL, Parag V (2009) Worldwide stroke incidence and early case fatality reported in 56 population-based studies: a systematic review. *Lancet Neurol* 8:355–369.
- [5] Aguilar, M. I., & Brott, T. G. (2011). Update in intracerebral hemorrhage. *The Neurohospitalist, 1(3), 148–159.*
- [6] Caceres, J. A., & Goldstein, J. N. (2012). Intracranial hemorrhage. *Emergency medicine clinics of North America, 30(3), 771–794.*
- [7] Bae HG, Lee KS, Yun IG, Bae WK, Choi SK, Byun BJ, et al. Rapid extension of hypertensive intracerebral hemorrhage. *Neurosurgery* 1992; 31:35–41.
- [8] Singh RV, Prusmack CJ, Morcos JJ. Spontaneous intra-cerebral hemorrhage: non-arteriovenous malformation. In: Winn HR, ed. *Youmans neurological surgery*. Philadelphia, PA: Saunders Publishers 2004. 1733–1768
- [9] Mendelow AD, Gregson BA, Rowan EN, Murray GD, Gholkar A, Mitchell PM, Investigators SI. Early surgery versus initial conservative treatment in patients with spontaneous supratentorial lobar intracerebral haematomas (STICH II): a randomised trial. *Lancet*. 2013;382:397–408
- [10] Alkhadrawy, S. M., Alaghory, I. M., & Selim, M. M. (2019). Surgical management of spontaneous intracerebral hemorrhage. *The Scientific Journal of Al-Azhar Medical Faculty, Girls, 3(1), 131.*
- [11] Lamichhane, S., Devbhandari, R., Tripathi, S., & Chapagain, M. (2021). Predictors of surgical outcome among patients with spontaneous supratentorial intracerebral hemorrhage: A prospective single institutional study. *Nepal Journal of Neuroscience, 18(2).*
- [12] Hessington, A., Tsitsopoulos, P. P., Fahlström, A., & Marklund, N. (2018). Favorable clinical outcome following surgical evacuation of deep-seated and lobar supratentorial intracerebral hemorrhage: a retrospective single-center analysis of 123 cases. *Acta neurochirurgica, 160(9), 1737-1747.*