

Conversion of Failed Hip Hemiarthroplasty to Total Hip Replacement

Ashraf.F.Abd El Galil, Ahmed.S.Allam, Ahmed.S.Risk and Saad.A.Shoulah

Orthopaedic Surgery Dept., Faculty of Medicine, Benha University

E-mail: dr.ashraf.fawzy11@gmail.com

Abstract

Background: Hip hemiarthroplasty, a common surgical intervention for femoral neck fractures and other hip pathologies, may sometimes lead to aseptic failure due to various complications. When such failure occurs, conversion to total hip replacement (THR) becomes necessary, posing unique surgical challenges. This study aimed to evaluate early results of Conversion of 30 cases of aseptic failed hip hemiarthroplasty (bipolar or unipolar) to total hip replacement. **Methods:** This study is a prospective analysis of 30 patients who sought treatment at Benha University Hospital, Nasser Institute Hospital, and El Kasr Elainy Hospital, presenting with failed hip hemiarthroplasty. These patients were followed up for 12 months as part of a short-term study. **Results:** The study included 30 patients, primarily male (73.3%), with a mean age of 63 ± 5 years. Acetabular erosion was the most common indication (43.3%). Intraoperative complications were minimal, with most patients experiencing no issues (93.3%). Postoperative complications included superficial infection (10%) and other less frequent complications. At one year, most patients had excellent Harris Hip Scores (80%). **Conclusions:** Transforming symptomatic hemiarthroplasty into THA is a secure alternative that yields favorable functional outcomes, albeit with slightly increased incidences of both intraoperative and postoperative complications.

Keywords: Hip, Hemiarthroplasty, Total Hip Replacement.

1. Introduction

Hip arthroplasty is a common surgical procedure employed to address a wide range of hip joint pathologies, including osteoarthritis, femoral neck fractures, and hip fractures in elderly patients^[1].

Hemiarthroplasty, in particular, has been a preferred treatment choice for patients with femoral neck fractures and other conditions where only the femoral side of the hip joint requires replacement. While hemiarthroplasty can offer significant relief from pain and functional improvements, it is not immune to complications. Among these complications, aseptic failure leading to discomfort, pain, and diminished joint function can significantly impact a patient's quality of life^[2].

Aseptic failure in hip hemiarthroplasty, which refers to failure unrelated to infection or periprosthetic fractures, often stems from issues in the acetabulum or femur. These issues may include acetabular erosion, protrusion, or malpositioning, as well as femoral stem migration or component loosening. When a hemiarthroplasty procedure fails in this manner, the revision or conversion to a total hip replacement (THR) becomes a necessary and complex surgical intervention^[3].

THR is the gold standard for the management of end-stage hip joint pathology, providing long-term pain relief, restoration of joint function, and improved patient mobility. However, the conversion of a failed hemiarthroplasty to THR presents unique challenges, including the removal of existing

implants, reconstruction of the acetabulum, and appropriate selection of THR components^[4].

Despite the increasing frequency of these conversion procedures, there is a noticeable paucity of comprehensive studies assessing the outcomes and complications associated with the conversion of failed hip hemiarthroplasty to THR. Understanding the early results and challenges in this conversion process is crucial to enhance patient care and refine surgical techniques^[5].

Therefore, the aim of this prospective study was to evaluate the early outcomes of converting 30 cases of aseptic failed hip hemiarthroplasty (both bipolar and unipolar) to total hip replacement.

2. Methods

Patients:

This study is a prospective analysis of 30 patients who underwent hip hemiarthroplasty conversions to total hip replacement (THR) due to aseptic failure, excluding infected prosthesis and periprosthetic fractures.

The study included 30 patients who sought treatment at Benha University Hospital, Nasser Institute Hospital, and El Kasr Elainy Hospital, presenting with failed hip hemiarthroplasty. These patients were followed up for 12 months as part of a short-term study.

Inclusion Criteria: The study included both male and female patients who experienced complications with their hemiarthroplasty due to issues such as acetabular erosion, femoral loosening, combined dislocation, or recurrent dislocation.

Patients were required to be active and motivated.

Exclusion Criteria: Patients with poor general health, non-active motivation, infected hemiarthroplasty, or periprosthetic fractures were excluded from the study.

Plan of Management of Failed Hip Hemiarthroplasty:

Preoperative Evaluation:

Personal History: This included patient details such as name, address, sex, occupation, age, and the affected side. **Complaints:** Patients reported issues such as startup pain and instability. **Duration Since Hemiarthroplasty:** The time between the initial hemiarthroplasty surgery and the development of complications was recorded. **Past History:** Any prior lower limb injuries or infections, along with the management methods (medical or surgical), were documented. **Clinical Examination:** This involved inspecting the affected area for skin condition, swelling, scars, muscle wasting, draining sinuses, foot position in cases of dislocation, limb alignment or deformities, and feeling for tenderness and warmth. **Passive range of motion, muscle power assessment, neurological examination, and gait analysis** were conducted whenever possible. **Local Assessment:** Neurovascular status and muscle power of the lower limb were evaluated. **Clinical Evaluation:** The Harris hip score was used for preoperative assessment. **Radiographic Examination:** This included plain X-rays in both anteroposterior and lateral positions. Indications for component revision were assessed using Kohler's line, acetabular tear drop, ischial lysis, and vertical migration criteria. Computed tomography was used to assess acetabular or femoral defects. **Laboratory Evaluation:** Complete blood count, erythrocyte sedimentation rate (ESR), C-reactive protein (CRP), and hip aspiration to rule out infection were conducted.

Operative Sheet:

Surgical details, including the date of surgery, operation duration, instruments used, prosthesis type, operative technique, and any complications, were recorded.

Postoperative Evaluation: Clinical evaluation using the Harris Hip Score, Radiological evaluation, and postoperative rehabilitation.

Method:

Surgical Technique:

Patient Positioning:

Surgical approaches were carried out with patients in the lateral position. Proper fixation and alignment of the trunk and pelvis were ensured to avoid pelvic malpositioning.

The patient's leg was positioned on a foam block.

Surgical Approaches: The selection of either the posterior or lateral approach hinged on the patient's prior surgical background and the necessity for adequate acetabular exposure. **Lateral Approach:** In this method, a longitudinal incision was made along the hip's lateral side, followed by a meticulous dissection to reveal the hip joint. **Posterior Approach:** The posterior approach, on the other hand, entailed an incision along the hip's posterior aspect, subsequently involving dissection to expose the hip joint. This technique facilitated optimal visibility and access to different parts of the acetabulum.

Removal of Cemented Prosthesis: The technique for removing cemented prosthesis depended on whether the stem was loose or not. If the stem was loose, it was extracted using a femoral stem extractor, whereas, if the stem was not loose, cement removal was performed before extraction.

Reconstruction of Acetabular Deficiencies: The technique for reconstructing acetabular deficiencies depended on the severity of the defect. In cases of minimal deficiency, acetabular reconstruction was performed using cementless cups. In cases of more extensive deficiencies, additional augmentations and grafting techniques were used to ensure secure implantation.

Femoral Preparation: Following acetabular reconstruction, femoral preparation was performed. Cementless stems were used for femoral reconstruction in most cases. The stems were placed according to the patient's anatomy and bone quality.

Prosthesis Implantation: The definitive prosthesis was implanted after both acetabular and femoral preparations. The prostheses used were cementless and suitable for the patient's anatomy.

Closure: After implantation, the wound was closed in layers using standard surgical techniques.

Postoperative Protocol: Postoperative management consisted of anticoagulation therapy for 3 months, 24 hours of systemic antibiotic therapy, and 7 days of indomethacin to prevent heterotopic ossification. Passive motion exercises commenced 24 hours after surgery, with suture removal after 2 weeks. The hip was abducted by 15 degrees with external rotation for the posterior approach and internal rotation for the lateral approach.

Rehabilitation Goals: The rehabilitation goals included protecting the graft, strengthening the abductors, and preventing dislocation.

Follow-Up Period: Patients were scheduled for follow-up visits at 2 weeks, 6 weeks, 3 months, 6 months, and 1 year, with periodic routine radiographs every 2 years. The postoperative program varied depending on factors such as the type of prosthesis (cemented or cementless), the presence of bone graft, and the patient's bone quality. There were two main programs:

Program 1: Partial weight-bearing for 6 weeks, followed by a gradual increase in weight-bearing over the next 6 weeks.

Program 2: Toe touch for 6 weeks, partial weight-bearing for another 6 weeks, and then a gradual increase in weight-bearing, with full weight-bearing after 3 months in cases of acetabular floor defects and bone graft usage. Patients were advised to use crutches or a cane for at least 3 months, depending on abductor strength and bone graft incorporation.

Methods of Outcome Evaluation:

We employed the Harris Hip Scale (HHS) as a means of evaluating the outcomes of hip surgery. This assessment tool is designed to gauge a range of hip-related issues and therapeutic interventions. The HHS comprises four key domains, namely pain, function, absence of deformity, and range of motion. The overall score provides insight into the quality of the outcome, with potential interpretations falling within the following categories: <70 (indicating a poor outcome), 70-80 (reflecting a fair outcome), 80-90 (indicating a good outcome), and >90 (representing an excellent outcome) [6].

Radiographic Evaluation: Radiographic evaluation involved anteroposterior and lateral views. The assessment included leg length, the position and inclination of the acetabular component, the position of the femoral stem, cement mantle thickness, screws of the cup, bone

graft, augment, cerclage of the femur, and trochanteric osteotomy.

Statistical analysis:

Data management and statistical analysis were conducted using SPSS version 28 (IBM, Armonk, NY, USA). To assess the normality of quantitative data, the Shapiro-Wilk test was employed, along with direct visualization. Depending on the normality distribution, quantitative data were presented as either means and standard deviations or medians and ranges. Meanwhile, categorical data were represented in terms of numbers and percentages. For the comparison of Harris hip scores at different time points, Cochran's Q test was utilized, and pairwise analyses were adjusted using Bonferroni's method. The independent t-test was applied to compare quantitative data based on the Harris Hip Score (HHS), while Fisher's exact test was used for the comparison of categorical data. All statistical tests were two-sided, and significance was defined as P values less than 0.05.

3. Results

This study was conducted on thirty patients who were candidates for Conversion of failed hip hemiarthroplasty to total hip replacement.

The mean age of the studied patients was 63 ± 5 years. There was a male predominance (73.3%). About one-quarter (23.3%) were smokers. One-third had co-morbidities (30%). More than half (53.3%) were home-related, one-third were community ambulators, and 13.3% were bedridden. The most frequent indication was acetabular erosion (43.3%), followed by femoral loosening (30%), acetabular and femoral causes (16.7%), and dislocation (10%) (Table 1).

Table (1) General characteristics of the studied patients

General characteristics		
Age (years)	Mean \pm SD	63 \pm 5
Gender		
Male	n (%)	22 (73.3)
Female	n (%)	8 (26.7)
Smoking	n (%)	7 (23.3)
Co-morbidity Status		
Bed ridden	n (%)	4 (13.3)
Home related	n (%)	16 (53.3)
Community ambulator	n (%)	10 (33.3)
Indications		
Acetabular erosion	n (%)	13 (43.3)

Femoral loosening	n (%)	9 (30)
Acetabular and femoral cause	n (%)	5 (16.7)
Dislocation	n (%)	3 (10)

Most patients had no intraoperative complications (93.3%). Only one patient had bleeding from muscular branches which can be controlled by ligation and oozing of blood as patient has bleeding tendency as he is renal patient on dialysis but good replacement by anaesthetist succeeded to control. and one had a periprosthetic fracture of greater trochanter and fixed by cerclage. The most frequent postoperative complication was superficial infection (10%). Other complications included periprosthetic fracture, dislocation, deep infection, sciatic palsy, DVT, trochanteric non-union, and heterotopic ossification (one patient for each). Only three patients (10%) needed revision (Table 2).

Table (2) Intra and postoperative complications in the studied patients.

	n (%)
Intraoperative complication	
Bleeding	1 (3.3)
Periprosthetic fracture	1 (3.3)
No complications	28 (93.3)
Postoperative complications	
Periprosthetic fracture	1 (3.3)
Dislocation	1 (3.3)
Superficial infection	3 (10)
Deep infection	1 (3.3)
Sciatic palsy	1 (3.3)
DVT	1 (3.3)
Trochanteric non-union	1 (3.3)
Heterotopic ossification	1 (3.3)
No complications	20 (66.7)
Need revision	3 (10)

DVT: Deep venous thrombosis

All patients showed poor HHS preoperatively. At one month, most patients (86.7%) demonstrated good HHS. Only 13.4% had fair (6.7%) and excellent (6.7%) HHS. At six months, more than half of the patients had excellent HHS (56.7%), and about one-third had good HHS. Only two patients had poor HHS. At one year, most patients (80%) had excellent HHS, while only 20% had poor and good HHS (10% for each) (Figure 1).

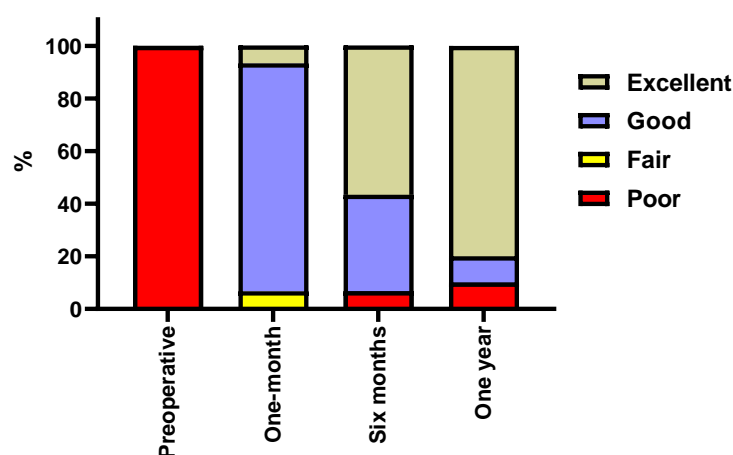


Fig. (1) Harris hip score of the studied patients at different times

The mean acetabular cup was 41 ± 5 . length, while one-third (36.7%) had longer limbs. No shortening was reported. Most patients had neutral femoral stems Periprosthetic lucency, migration of (90%). About two-thirds (63.3%) had equal leg

components, osteolysis, and heterotopic ossification were reported in one patient for each. Most patients (96.7%) demonstrated good sclerotic reactions. A significant difference was reported in HHS between preoperative, one-month, six-month, and one-

year measures ($P < 0.001$). Post hoc analysis revealed that good to excellent response was significantly higher at 1-month (93.3%), six months (93.3%), and one year (90%) than preoperative measure (0%) (Table 3).

Table (3) Radiological findings at 1 & 3 months and at 1 year.

Radiological findings	Mean \pm SD	
Acetabular cup		41 \pm 5
Femoral stem		
Neutral	n (%)	27 (90)
Valgus	n (%)	2 (6.7)
Verus	n (%)	1 (3.3)
Leg length		
Equal length	n (%)	19 (63.3)
Longer limb	n (%)	11 (36.7)
Radiological findings at 1 year		n (%)
Periprosthetic lucency		1 (3.3)
Migration of components		1 (3.3)
Osteolysis		1 (3.3)
Heterotopic ossification		1 (3.3)
Sclerotic reaction		
Good		29 (96.7)
Bad		1 (3.3)

Patients were classified according to HHS at the end of follow-up into 24 patients with excellent HHS and 6 without. No significant differences were reported regarding age ($P = 0.353$), gender ($P = 0.546$), smoking ($P = 0.290$), co-morbidity ($P = 0.329$), patient status ($P = 0.830$), indications ($P = 0.108$), approach ($P = 0.302$), transtrochanteric ($P = 0.571$), preoperative stem ($P = 0.155$), postoperative stem ($P = 0.3$), and postoperative cup (0.254) (Table 4).

Table (4) Comparison of Harris hip score at different times

HHS		Preoperative	At 1 month	At six months	At 1-year	P-value
Poor to fair	n (%)	30 (100) ^a	2 (6.7) ^b	2 (6.7) ^b	3 (10) ^b	< 0.001*
Good to excellent	n (%)	0 (0)	28 (93.3)	28 (93.3)	27 (90)	

* Significant P-value; Different small letters between any two times indicate statistical significance; HHS: Harris hip score

4. Discussion

In our research, we observed favorable outcomes when converting painful hemiarthroplasty in terms of pain relief and functional scores. We found our functional results to be highly promising. Before the surgery, all patients displayed poor Harris Hip Scores, with less than 70%. After 12 months, 80% of the patients achieved excellent HHS, 10% had a good outcome, and the remaining 10% had less satisfactory results.

Our study revealed a low incidence of complications, including one case of dislocation, one periprosthetic fracture, three instances of superficial infection, one deep infection, one case of deep vein thrombosis, one occurrence of sciatic nerve palsy, and one case of heterotopic ossification. The only case of loosening occurred in the context of deep

infection. A revision hip surgery was required in 10% of the cases, with three cases necessitating revision due to deep infection, recurrent dislocation, and periprosthetic fracture.

Our series differs from previous studies in one important aspect: a significant proportion of acetabular components (83.3%) and the majority of femoral components (73.3%) used in our series were uncemented. This distinction likely contributed to the lower rates of loosening. Another contributing factor to reduced loosening rates was the complete removal of the fibrous endosteal membrane.

The occurrence of dislocation following conversion arthroplasty has been reported to range from 0% to 50% in different series. In our case, we experienced a single instance of dislocation shortly after the

surgery. We attribute the likelihood of postoperative instability to factors such as old age, muscle weakness, and extensive soft tissue release. However, in our study, we observed a reduced incidence of dislocation, primarily due to the implementation of a dual mobility cup, an acetabular lipped liner, and the use of large heads, especially in high-risk patients for dislocation. In contrast to other studies, we only encountered one periprosthetic fracture in our research, which can be attributed to the trochanteric osteotomy technique used in cases where the extraction of the femoral stem proved to be challenging.

In one of the earliest studies focusing on conversion arthroplasty conducted by Amstutz and Smith, they documented a notably high occurrence of both intraoperative and postoperative complications. Their study encompassed 41 patients who underwent conversion arthroplasty. They encountered five proximal femoral fractures during the surgery, along with two cases of medial cortex perforations resulting in stem protrusion. Additionally, two cases exhibited postoperative instability, while two others suffered from infections. Three patients experienced deep venous thrombosis, and six patients (comprising 14.6% of the sample) exhibited progressive loosening. By the end of their follow-up period, which had a mean duration of 36 months, three patients required revision surgery^[7].

Conversely, Hammad and Abdel-Aal reported no instances of loosening in their series of 47 patients who underwent conversion arthroplasty, following an average follow-up of 44 months. They suggested that the lower rate of loosening in their study, compared to previous research, might be attributed to improvements in cementing techniques and stem design. They also proposed that femoral side failure could be linked to extensive resorption of endosteal bone when the hemiarthroplasty stem was loose or due to endosteal bone damage during revision. Furthermore, the toggling of the stem may result in the formation of a dense fibrous membrane that adheres firmly and may not be entirely removed during revision, potentially compromising subsequent cemented fixation. It has been theorized that fragments of such a fibrous membrane are highly metabolically active, leading to the production of Prostaglandin E₂, collagenase, and Interleukin1b, all of which could contribute to the resorption of adjacent bone^[8].

Sharkey and colleagues, in their study involving 45 patients who underwent the conversion of hemiarthroplasty to total hip

arthroplasty (THA), observed that 20% of the patients continued to experience discomfort in the groin or buttock area following THA. Interestingly, they were unable to identify any specific factors that could reliably predict an unsuccessful outcome. Therefore, Sharkey et al. recommended that patients be informed of the possibility of experiencing postoperative groin pain as part of their surgical consultation^[9].

In our own study, we observed a noteworthy enhancement in the functional status of patients who underwent conversion surgery, regardless of the initial indication for the procedure. It's worth noting that there is limited literature available regarding the outcomes of converting hemiarthroplasty. In a previous report, one author discussed a group of 45 patients who initially experienced groin or buttock pain after hemiarthroplasty and subsequently underwent revision surgery to THA. Remarkably, this revision surgery successfully alleviated the discomfort in 40 out of 45 patients, representing an 89% improvement rate. Among the 31 patients who had received bipolar hemiarthroplasty in that study, only 5 still reported persistent pain following conversion. Importantly, the study found no significant difference in the occurrence of stubborn groin pain between patients who initially received unipolar and bipolar hemiarthroplasties.

Sierra and Cabanela conducted a study involving 132 cases of conversion to total hip arthroplasty (THA) following previous hemiarthroplasties performed for femoral neck fractures. Their findings revealed long-lasting pain relief, with 86% of patients reporting either no pain or only mild discomfort, while 14% experienced moderate to severe pain. These results were obtained during an average follow-up period of 7.1 years. Sierra and Cabanela also documented a reoperation rate of 6.75%, primarily due to aseptic loosening, with 6% of cases related to the femur and 0.7% to the acetabulum. Notably, they opted for cemented femoral components in 88% of the patients, and the higher rate of revisions associated with cemented prostheses was attributed to factors such as extensive endosteal bone resorption, incomplete removal of the surrounding membrane, and resultant suboptimal cement mantle quality. In contrast, our own experience demonstrates exceptional outcomes with the utilization of uncemented prostheses^[10].

In a more extensive study encompassing 132 cases of hemiarthroplasties converted to total hip arthroplasty (THA), Sierra and Cabanela documented a 10%

occurrence of loosening during an average follow-up period of 7.1 years. Furthermore, they encountered significant complications in 45% of cases, which included 12 intraoperative femoral fractures (accounting for 9% of the cases) and 13 dislocations (equating to 9.8%). As a result of these findings, they concluded that converting endoprostheses to THAs following femoral neck fractures is associated with elevated rates of complications and loosening^[10].

Sanket R. Diwanji and colleagues conducted a study that examined the outcomes of 25 patients who underwent the conversion of bipolar hemiarthroplasty to THA. The follow-up period averaged 7.2 years and included patients with various conditions: acetabular erosion with a well-fixed femoral stem in 13 cases, acetabular erosion with femoral loosening in 8 cases, and periprosthetic fractures in 4 cases. The study found a notable improvement in the average Harris Hip Score, which increased from 41 (ranging from 34 to 67) before the conversion to 85 (ranging from 65 to 95) at the final follow-up. However, there were some complications observed, including 2 cases of recurrent dislocations, 2 dislocations, 1 instance of acetabular loosening, and 1 case of trochanteric nonunion. In one case, revision of the acetabular component was necessary. In conclusion, the conversion of THA following symptomatic bipolar arthroplasty demonstrated the potential for providing reliable pain relief and functional improvement.^[11]

Afshin Taheriazam conducted a study focused on the outcomes of 138 patients who underwent the conversion of failed hemiarthroplasty to total hip arthroplasty. The patients received clinical evaluations at various intervals: 1 month, 6 months, 1 year, and subsequently on an annual basis. The average duration of the follow-up period was 42 months, with a range of 36 to 60 months. The Harris Hip Score (HHS) showed significant improvement, with the mean preoperative score of 44.93 ± 8.40 increasing to 95.41 ± 2.27 at the final follow-up assessment. During the course of the study, dislocation was observed in 6 patients, constituting 4.34% of the cases^[12].

5. Conclusion

The transformation of symptomatic hemiarthroplasty into total hip arthroplasty (THA) represents a secure choice that yields favorable functional outcomes, albeit with slightly increased incidences of both intraoperative and postoperative complications.

References

- [1] Z. Hayat, M. Varacallo. Surgical management of femoral neck fractures. StatPearls [Internet]. 2023
- [2] E. Lutnick, J. Kang, D.M. Freccero. Surgical Treatment of Femoral Neck Fractures: A Brief Review. *Geriatrics (Basel)*;5. 2020
- [3] T.W. Huang, C.H. Chang, F.C. Chang, C.C. Chen, K.C. Huang, M.S. Lee, et al. Results of Conversion from Failed Austin-Moore Hemiarthroplasty to Cementless Total Hip Arthroplasty in Octogenarian Patients with Advanced Acetabular Erosion: A Minimum of 5 Years of Follow-Up. *Biomed Res Int*;2019:7814602. 2019
- [4] L. Bayam, E. Drampalos, H. Nagai, P. Kay. Conversion of Failed Hip Hemiarthroplasty to Low Friction Arthroplasty (LFA). *J Clin Med*;8. 2019
- [5] N.M. Hernandez, K.M. Fruth, D.R. Larson, H.M. Kremers, R.J. Sierra. Conversion of Failed Hemiarthroplasty to Total Hip Arthroplasty Remains High Risk for Subsequent Complications. *J Arthroplasty*;34:2030-6. 2019
- [6] K. Vishwanathan, K. Akbari, A.J. Patel. Is the modified Harris hip score valid and responsive instrument for outcome assessment in the Indian population with peritrochanteric fractures? *J Orthop*;15:40-6. 2018
- [7] H.C. Amstutz, R.K. Smith. Total hip replacement following failed femoral hemiarthroplasty. *J Bone Joint Surg Am*;61:1161-6. 1979
- [8] A. Hammad, A. Abdel-Aal. Conversion total hip arthroplasty: functional outcome in Egyptian population. *Acta Orthop Belg*;72:549-54. 2006
- [9] P.F. Sharkey, R. Rao, W.J. Hozack, R.H. Rothman, C. Carey. Conversion of hemiarthroplasty to total hip arthroplasty: can groin pain be eliminated? *J Arthroplasty*;13:627-30. 1998
- [10] R.J. Sierra, M.E. Cabanela. Conversion of failed hip hemiarthroplasties after femoral neck fractures. *Clin Orthop Relat Res*;129-39. 2002
- [11] S.R. Diwanji, S.K. Kim, J.K. Seon, S.J. Park, T.R. Yoon. Clinical results of conversion total hip arthroplasty after failed bipolar hemiarthroplasty. *J Arthroplasty*;23:1009-15. 2008
- [12] A. Taheriazam, A. Saeidinia. Conversion of failed hemiarthroplasty to total hip arthroplasty: A short-term follow-up study. *Medicine (Baltimore)*;96:e8235. 2017