

## Melasma: Background, pathogenesis, diagnosis and treatment lines

Rami R.Affas, Hanan H.Sabry, and Samah E.Ibrahim

Dermatology, Venerology and Andrology dept., Faculty Of medicine, Benha University

E-mail : ramyraf80@gmail.com

### Abstract

**Background:** Melasma, symmetrical brown macules in sunlight-exposed regions, is a common acquired condition. Several treatments have mixed effectiveness and tolerance. **Objective:** This page discusses melasma epidemiology, clinical features, diagnosis, and therapy. Melasma aetiology, pathophysiology, clinical images, and decrease up to 2024 were found in Medline databases (Pub Med and Medscape). One year after giving birth, pregnancy-related melasma generally disappears with treatment. Six percent spontaneous remission. About 30% of individuals have pigmentary consequences. Oral contraceptive users and those with darker pigmented melasma have higher persistence. Pregnant women having a history of several pregnancies are more likely to have melasma for the first time Melasma, a common skin ailment, causes dark spots. It is more prevalent in childbearing women and symmetrical the illness reports were mostly female, with an estimated ratio of 9 or 10 females to 1 man. Melasma is more common in pregnant women, supporting its hormonal cause. High oestrogen, progesterone, and melanocortin levels during pregnancy. studies that did not meet inclusion requirements were excluded. Ethical approval, eligibility criteria, controls, information, and evaluation measures were study quality assessment factors. A data collecting form was used to independently extract data from each qualifying research for our study results.

**Keywords:** Melasma, Cathepsins; Treatment of melasma.

### Introduction

Melasma, a common skin ailment, causes dark spots. It is more prevalent in childbearing women and symmetrical (1). The incidence varies by ethnicity and geography from 8.8% to 40% (2).

### Materials and methods

**Data Sources:** Melasma aetiology, pathophysiology, clinical images, and decrease up to 2024 were found in Medline databases (Pub Med and Medscape).

**Study Selection:** Inclusion was independently evaluated for all trials. They were included if they met these criteria: 1. Published in English. 2. In peer-reviewed journals. 3. Review: melasma aetiology, pathophysiology, clinical images.

**Data Extraction:** Studies that did not meet inclusion requirements

were excluded. Ethical approval, eligibility criteria, controls, information, and evaluation measures were study quality assessment factors. A data collecting form was used to independently extract data from each qualifying research for our study results.

### Review of literature:

#### Melasma

Melasma, also known as chloasma, is a disorder in which individuals produce too much melanin, causing localised, long-lasting skin colouring. Women are more affected by the bilateral sun-exposed condition. Melasma in pregnant women is called the pregnancy mask (3).

#### Epidemiology:

Melasma affects all ethnicities and populations. According to epidemiological study, darker skin

tones and intertropical Americas residents with higher UVR exposure are more likely to develop the disorder (4).

The illness reports were mostly female, with an estimated ratio of 9 or 10 females to 1 man. Melasma is more common in pregnant women, supporting its hormonal cause. High oestrogen, progesterone, and melanocortin levels during pregnancy may induce this (4).

One year after giving birth, pregnancy-related melasma generally disappears with treatment. Six percent spontaneous remission. About 30% of individuals have pigmentary consequences. Oral contraceptive users and those with darker pigmented melasma have higher persistence. Pregnant women having a history of several pregnancies are more likely to have melasma for the first time (4).

#### **Pathogenesis:**

Melasma has a complicated aetiology. Melasma was caused by UV exposure, genetics, and hormones.

##### **1- UV irradiation:**

Clinical and experimental studies shows that UV exposure causes and worsens melasma. UV exposure activates inducible nitric oxide and boosts melanogenesis, producing reactive oxygen species (ROS). Melasma patients have higher oxidative stress levels than healthy people (5).

Keratinocytes and fibroblasts enhance melanogenesis after UV and visible light exposure. UV and visible light-induced pigmentation involves the production of stem cell factor (SCF), the tyrosine kinase receptor ligand. This route promotes melanocyte growth (5).

VEGF, released by keratinocytes after UV exposure, may also boost human melanocyte development in a lab. Melasma melanocytes may be more active due to this (5).

##### **2- Genetic predisposition:**

Family history is a risk factor for melasma, suggesting a genetic predisposition. Several studies show that 55–64% of this disease patients have a good family history. This process involves genes associated to pigment formation, inflammation, hormones, and maybe vascular responses (6).

##### **3- Hormonal factors:**

Due of its greater prevalence during pregnancy, oral contraceptives, and other hormonal therapies, melasma is strongly linked to hormones. Immunohistochemistry showed that the progesterone receptor was upregulated in the epidermis of affected skin compared to unaffected skin (7).

Oestrogen receptor protein was also elevated in the dermis and blood vessels. Oestrogens stimulate melanocyte pigmentation via binding to nuclear receptors and non-genomically targeting melanocytes. They increase melanocortin type 1 receptor (MC1R) expression in cultured melanocytes, which contribute to melasma (7).

Stress-related hormones including ACTH and MSH trigger melanocortin receptors in melanocytes, starting melanogenesis. Stress and depression increased the risk of melasma (7).

##### **Clinical presentation:**

Melasma has brownish macules with irregular shapes and well-defined edges. It appears on sun-exposed areas including the face, neck, and sometimes the arms and chest. Clinical distribution divides facial melasma lesions into centrofacial and peripheral groups. Centrofacial lesions mainly affect the glabellar, frontal, nasal, zygomatic, upper lip, and chin. This peripheral disease affects the fronto-temporal, preauricular, and mandibular branches (8).

Melasma outside the face might be linked to other facial patterns. Hyperpigmented, asymmetrical skin discolourations on the arms, forearms, neck, chest, and back are signs of extrafacial melasma. Upper limb melasmas are more common in older women after menopause and may be connected to hormone replacement therapy (8).

#### Diagnosis:

##### Investigations:

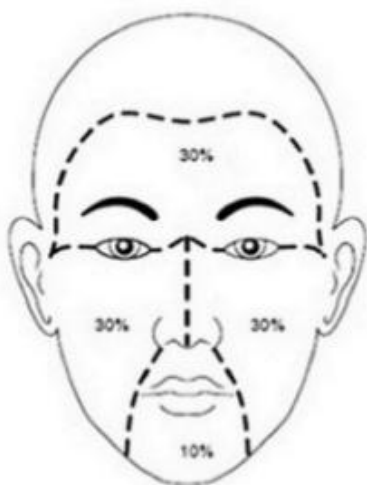
**1- Wood's lamp examination** (340 to 400nm) shows impaired skin pigmentation. Melasmas that are more acute under Wood's light react better to topical therapies (9).

**2- Dermoscopy of melasma** reveals notable modifications. The vascular component is visible. Melanin

density and position are determined by pigment network regularity and colour intensity (9).

**3- Colorimetry, mexametry, and the MASI (Melasma Area and Severity Index) score** to assess facial melasma severity. The MASI score is established by facial inspection. Three characteristics are assessed: affected area (A), hyperpigmentation (D), and pigmentation uniformity (H). The forehead (F), right malar region (MR), left malar region (ML), and chin (C) divide the face. The final MASI score is computed by summing pigmentation intensity and homogeneity values and multiplying by the area score and multiplication factor for each location (10). (Figure 1)

#### Melasma Area and Severity Index MASI Score



The area (A) of melasma involvement is graded from 0 to 6:

- 0 = no involvement
- 1 = less than 10% involvement
- 2 = 10% to 29% involvement
- 3 = 30% to 49% involvement
- 4 = 50% to 69% involvement
- 5 = 70% to 89% involvement

The darkness of pigmentation (D) and homogeneity (H) graded from 0 to 4:

- 0 = absent
- 1 = slight
- 2 = mild
- 3 = marked
- 4 = maximum

Fig. 1: MASI score (10)

#### Treatments for melasma

##### Topical treatment:

##### Hydroquinone (HQ):

Hydroquinone (HQ) inhibits tyrosinase, preventing dopa from becoming melanin. The suppression of

DNA and RNA creation, melanosome breakdown, and melanocyte death are further possible mechanisms. Extended use of high dosages of HQ may cause permanent depigmentation. Usually used at 2%–5% doses. HQ causes

irritation, contact dermatitis, postinflammatory pigmentation, and

#### **Retinoids:**

Tyrosinase is inhibited by retinoic acid, vitamin A acid, or tretinoin, which blocks the enzyme's transcription. Melanin synthesis is halted because it impedes the dopachrome conversion factor. By increasing the production of new skin cells, retinoic acid (RA) reduces hyperpigmentation. Redness, flakes of skin, and post-inflammatory hyperpigmentation are some of the negative side effects reported from using concentrations between 0.05% and 0.1% (12).

Melasma has responded well to treatment with RA 0.1%. Comparing the two groups, the tretinoin group had a 32% decline in MASI scores and the vehicle control group a 10% decrease. A significant decrease in epidermal pigmentation was seen in the RA group as compared to the control group, according to the histological study. Mild retinoid dermatitis was the only adverse effect reported by 67% of RA patients (12).

#### **Azelaic acid:**

By blocking mitochondrial oxidoreductase activity and DNA synthesis, azelaic acid causes melanocytes to undergo antiproliferative and cytotoxic consequences. Also, in lab conditions, it shows just a little amount of competitive inhibition of tyrosinase. Creams with concentrations of 15% to 20% azelaic acid are commercially available. Localised burning and itching were the most common and short-lived adverse effects of azelaic acid therapy (13).

#### **Corticosteroids:**

Has dual functions as an anti-inflammatory and a pigment-inhibiting agent by non-selectively reducing melanogenesis. Taking corticosteroids by themselves is not likely to provide

nail whitening (11).

greater results than using depigmenting medications. Although corticosteroids have the ability to decrease melanogenesis on their own, there is currently no proof that they effectively treat melasma in the long run. (14) have noted that telangiectasias, acne, epidermal atrophy, striae, and hypopigmentation may emerge after long-term steroid use.

#### **Vitamin C iontophoresis:**

Vitamin C reduces levels of oxidised melanin and inhibits melanin synthesis. A method called iontophoresis has been used to improve vitamin C absorption via the skin. A little electric shock, itching, redness, burning, and facial dryness are some of the most common adverse effects of this medicine (15).

#### **N-acetyl-4-S-cysteaminylphenol:**

The skin-lightening effects of phenolic and catecholic compounds are substantial. Phenol, catechol, and sulphur were used in the synthesis of N-acetyl-4-S-cysteaminylphenol, a melanocytotoxic chemical. A decrease in both the number of active melanocytes and the number of melanosomes transported to keratinocytes causes therapy-induced depigmentation (16).

#### **Melatonin and Glutathione:**

The pineal gland secretes the potent antioxidant melatonin, which scavenges free radicals. Glutathione peroxidase, glutathione reductase, and superoxide dismutase are among the antioxidant enzymes that it activates. The  $\alpha$ -melanocyte-stimulating hormone receptors are further blocked by melatonin (17).

A powerful endogenous antioxidant, glutathione (GSH) is produced by human cells. Glutamate, cysteine, and glycine are its three amino acid components. Skin

lightening occurs due to processes that include tyrosinase inhibition and the ability to switch eumelanin production to pheomelanin (18).

#### **Tranexamic acid:**

The amino acid lysine is the precursor of tranexamic acid, which has anti-melanogenic and anti-angiogenic properties. It slows down melanin production by blocking the plasminogen/plasmin pathway. This inhibitor reduces melasma-related skin pigmentation by blocking the interactions between keratinocytes and melanocytes. Also, it may turn back the clock on melasma-related changes to the skin, such less redness and fewer blood vessels (19).

#### **Physical treatment:**

1. **Chemical peel:** Chemical peels, which include a combination of acids such kojic acid, salicylic acid, tretinoin, and glycolic acid, are a successful method for treating melasma. Melasma treatments have expanded to include chemical peels due to their ability to speed up the skin's natural renewal process and increase the turnover of skin cells known as keratinocytes. It is usual practice to use chemical peels with other topical treatments. Redness, post-inflammatory hyperpigmentation, and crust development were the adverse effects observed (20).
2. **Microneedling:** Microneedling is a method that creates microscopic holes in the skin to introduce topical medicines into the dermis in the form of minuscule dosages. Microneedling has the potential to induce a favourable healing response in the skin by puncturing it. In comparison to more conventional topical approaches, this one is safer. More effective and consistent medication delivery to the skin's dermal and epidermal

layers may result from this process (21).

3. **Laser therapy:** By focussing their heat, lasers may target certain skin chromophores. Because of their reduced risk of inducing inflammation and subsequent pigment change, non-ablative lasers are better than ablative lasers for treating melasma. The chromophore melanin is the only target of non-ablative lasers. Unfortunately, laser therapy is not yet safe enough to be used alone on melasma patients. An alternate energy source called monopolar radiofrequency (RF) has been used to treat melasma. (22) found that radiofrequency (RF) may cause biostimulation of cells, oxygenation inside cells, and dilated blood vessels.

#### **References**

- [1] Abdalla, M. A. (2021). Melasma Clinical Features, Diagnosis, Epidemiology and Etiology: An Update Review. *Siriraj Medical Journal*, 73(12), 841-850.
- [2] Aishwarya, K., Bhagwat, P. V., & John, N. (2020). Current concepts in melasma-a review article. *Journal of Skin and Sexually Transmitted Diseases*, 2(1), 13-17.
- [3] Artzi, O., Horovitz, T., Bar-Ilan, E., Shehadeh, W., Koren, A., Zusmanovitch, L., ... & Mashiah, J. (2021). The pathogenesis of melasma and implications for treatment. *Journal of Cosmetic Dermatology*, 20(11), 3432-3445.
- [4] Bailey, A. J. M., Li, H. O. Y., Tan, M. G., Cheng, W., & Dover, J. S. (2022). Microneedling as an adjuvant to topical therapies for melasma: A systematic review and meta-analysis. *Journal of the American Academy of Dermatology*, 86(4), 797-810.

- [5] Bansal, A., Ailawadi, P., & Sarkar, R. (2021). Treatment of Melasma: Future Directions. *Melasma: A Monograph*, 106.
- [6] de Freitas, A. C. P., Rigon, R. B., Bagatin, E., & Leonardi, G. R. (2023). Perspectives of topical formulations for melasma. *International Journal of Dermatology*, 62(2), 260-268.
- [7] Doolan, B. J., & Gupta, M. (2021). Melasma. *Australian Journal of General Practice*, 50(12), 880-885.
- [8] Espósito, A. C. C., Cassiano, D. P., da Silva, C. N., Lima, P. B., Dias, J. A., Hassun, K., ... & Miot, H. A. (2022). Update on Melasma—Part I: Pathogenesis. *Dermatology and Therapy*, 12(9), 1967-1988.
- [9] Hagag, M. M., & Abd Allah, S. S. (2022). The effect of topical nano vitamin-C iontophoresis versus the effect of trichloroacetic acid 20% peel in treatment of melasma. *Menoufia Medical Journal*, 35(2), 489.
- [10] Hoque, F., McGrath, J., & Shaude, S. E. (2022). Melasma (Chloasma): Pathogenesis and Treatment. *Journal of Biotechnology and Biomedicine*, 5(4), 236-243.
- [11] Karim, M., Diep, D., Onikoyi, O., Teymour, S., & Lal, K. (2023). Chemical peels for the management of melasma and hyperpigmentation. *Dermatologic Reviews*, 4(1), 53-57.
- [12] Khanna, R., Nowah, A., Morris, D., & Desai, S. R. (2023). Pathogenesis of melasma. *Dermatological Reviews*, 4(1), 12-16.
- [13] King, S., Campbell, J., Rowe, R., Daly, M. L., Moncrieff, G., & Maybury, C. (2023). A systematic review to evaluate the efficacy of azelaic acid in the management of acne, rosacea, melasma and skin aging. *Journal of Cosmetic Dermatology*, 22(10), 2650-2662.
- [14] Kumaran, M. S., Narayan R, V., Kaushik, A., Bishnoi, A., Vinay, K., & Parsad, D. (2021). Clinico-epidemiological profile and long term follow up in melasma. *Dermatologic Therapy*, 34(6), e15143.
- [15] Lai, D., Zhou, S., Cheng, S., Liu, H., & Cui, Y. (2022). Laser therapy in the treatment of melasma: a systematic review and meta-analysis. *Lasers in Medical Science*, 37(4), 2099-2110.
- [16] Liu, W., Chen, Q., & Xia, Y. (2023). New mechanistic insights of melasma. *Clinical, Cosmetic and Investigational Dermatology*, 429-442.
- [17] Mahajan, V. K., Patil, A., Blicharz, L., Kassir, M., Konnikov, N., Gold, M. H., ... & Goldust, M. (2022). Medical therapies for melasma. *Journal of cosmetic dermatology*, 21(9), 3707-3728.
- [18] Majid, I., & Aleem, S. (2021). Melasma: Update on Epidemiology, Clinical Presentation, Assessment, and Scoring. *Journal of Skin and Stem Cell*, 8(4).
- [19] Navya, A., & Pai, V. (2022). Comparison of dermoscope and woods lamp as a tool to study melanin depth in melasma. *Indian Dermatology Online Journal*, 13(3), 366.
- [20] Punchihewa, N., & Rodrigues, M. (2023). A comprehensive review of dermoscopy in Melasma. *Clinical and Experimental Dermatology*, 11ad266.
- [21] Rao, S. K., Rajashekar, T. S., & Ashraf, A. (2022). Efficacy of intralesional tranexamic acid in

- melasma: Assessment with Melasma Area Severity Index and Dermatology Quality of Life Index. *Turkderm-Turk Arch Dermatol Venereol*, 56, 58-63.
- [22] Wiraguna, A. A. G. P., Hari, E. D., & Praharsini, I. G. A. A. (2020). Correlation between glutathione plasma with degree severity of melasma in Balinese women. *Clinical, Cosmetic and Investigational Dermatology*, 455-459