

## Minimally Invasive Technique for Treatment of Calcaneal Fractures

Sherin A. Khalil, Hossam E. Elbijawy, Hosam E. Farag and Mustafa T. Nawar

Orthopedic surgery Dept., Faculty of Medicine, Benha Univ., Benha, Egypt

E-mail: dr\_nawwar@yahoo.com

### Abstract

**Background:** The purpose of this study is to compare the clinical and radiographic outcomes of a short lateral subtalar approach with screw fixation for the treatment of displaced calcaneal fractures. Cases and procedures; The research included patients with intra-articular calcaneus fractures who presented to Banha University Hospitals and El-Mataria Teaching Hospital between January 2019 and June 2022 and who were treated with Limited open reduction and internal fixation through short lateral subtalar approach. The average age of the patients was 35 years. Twenty-eight of the fractures were diagnosed as joint depression fractures, while two were classified as tongue type fractures. Among the total number of fractures, 19 were classed as Sanders II, while 11 were classified as Sanders III. The articular surface of each patient was reduced directly, while the extraarticular component was reduced indirectly and fixed percutaneously under fluoroscopic guidance. Those numbers add up to a mean AOFAS ankle/hindfoot score of 91.73 and a mean Maryland foot score of 95.09. In all, 13.3 months were spent following up with patients. Two patients had superficial wound infections, and one patient developed sural nerve dyesthesia, both of which responded well to non-invasive therapies. Physiotherapy and pregabalin were effective treatments for four patients with complex regional pain syndrome (CRPS). 5 occurrences of tenderness at the screw site led to the removal of the screws. Both the AOFAS ankle/hindfoot score and the Maryland foot score were shown to be strongly correlated with the amount of time that passed between the injury and the surgery. **Conclusion:** It has been shown that a restricted lateral subtalar approach with screw fixation is an efficient, risk-free, and repeatable means of treating a sandler type II or III calcaneal fracture.

**Keywords:** Intraarticular calcaneal fractures, sinus tarsi approach, Sanders classification

### 1. Introduction

The calcaneus is often broken in the clinic as a consequence of high-energy trauma. Approximately 60% of all tarsal injuries are fractures, making up 2% of total body fractures. A large percentage of trauma patients are unable to return to their previous line of work due to chronic pain and incapacity, and this is especially true if they get substandard care. 2

The most popular of these stated categories is the Essex-Lopresti classification.

It was divided into two distinct types: To begin, there are fractures that extend into the subtalar joint (75%), which may be further classified as either tongue fractures or joint depression fractures. joint-sparing fractures (25 percent ). 4,5 This categorization helped the surgeon

choose the best course of therapy, but it didn't tell us anything about the patients' long-term prospects. 7

CT scanning categorization was devised by Sanders et al. based on coronal section counts and locations of articular fracture fragments<sup>8</sup>. A type-I fracture was defined as any non-displaced articular fracture with no more than three fracture lines. Fractures of the posterior facet were classified as type II if they consisted of two separate pieces. Fractures of the type III kind were those broken up into three pieces. More than four articular fragments were common in type IV fractures because to their extreme comminution. 9 The categorization proved helpful in making therapeutic and prognostic decisions (Fig.1).

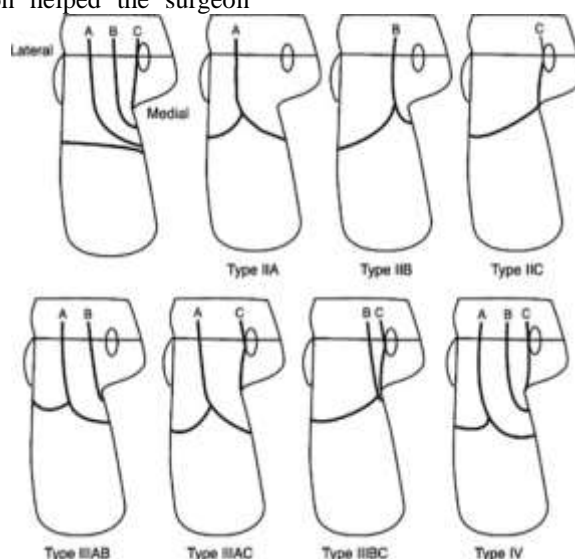


Fig (1) Drawing showing the Sanders classification.<sup>10</sup>

Conservative care and surgical management are the two categories of treatment for displaced intra-articular calcaneal fractures. The latter group includes procedures like the primary arthrodesis, which is a kind of internal fixation, and the open and percutaneous reduction and internal fixation techniques (PA). Since ORIF may physically reconstruct the subtalar joint and often results in good to exceptional functional outcomes for displaced intra-articular fractures of the calcaneus, it has become the treatment of choice amongst specialists. Arthritis of the subtalar joint might develop if the articular surface is not reshaped. It is common practise to do open reduction and internal fixation by a lateral 'L' shaped incision. The articular surface is exposed perfectly. Yet, this method is associated with a high rate of problems during wound healing. 11 A minor incision technique using the sinus tarsi has been developed to reduce wound problems.

## 2. Materials And Methods

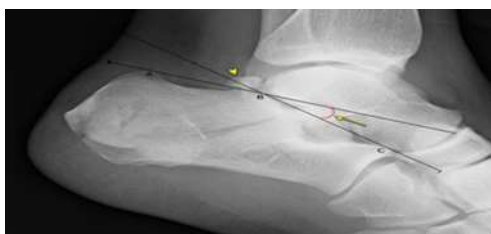
The study was conducted on 27 patients with 30 fracture calcaneus from January 2019 till June 2022 including patients with intra-articular fractures of the calcaneus presenting to Benha University Hospitals and El-Mataria Teaching Hospital, treated by Limited open reduction and internal fixation via short lateral subtalar approach (technique described by Weber et al). The mean age for patients was 35.3 years (from 18 to 56 y). Out of

the 27 studied patients, 23 were males and 4 were females. Follow up period was over 24 months.

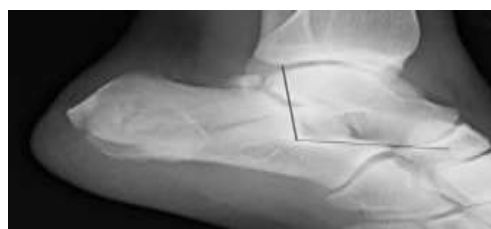Patients with closed displaced intra-articular fractures of the calcaneus are included. According to Sanders' classification, only type II and III fractures were included and According Essex-Lopresti classification, both joint depression type or tongue type were included. Patients with open fractures, Intra-articular fractures, Sanders' type I and type IV, Extra-articular fractures are excluded.

Preoperative assessment included radiographs (lateral, anteroposterior, axial and Broden's view) and computed tomography (CT) imaging of the affected ankle. Lateral radiographs were used to assess the Bohler's angle and angle of Gissane, loss of height of the calcaneum and displacement of the posterior facet (Figure 2, 3). The anteroposterior radiograph shows extension of the fracture line into the calcaneocuboid joint.<sup>9</sup>

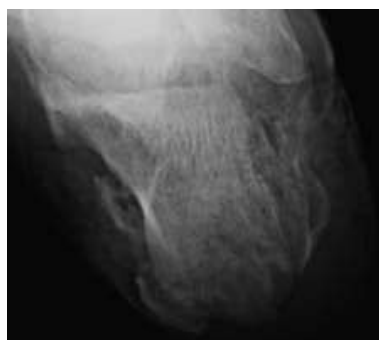
The Harris axial radiograph of the heel: allows visualization of the joint surface as well as loss of height, increase in width, and angulation of the tuberosity fragment.<sup>9</sup> (Figure 4). Broden's view was used to evaluate the articular surfaces of the posterior facet of the calcaneum. CT scan of the ankle was used to assess size and number of fracture fragments, displacement of posterior facet and sustentaculum tali and impingement of lateral malleolus on the calcaneal tuberosity (Figure 5).



**Fig. (2)** lateral radiograph show reduction of Bohlers angle.



**Fig. (3)** lateral radiograph shows the angle of Gissane.



**Fig. (4)** radiograph showing the Harris axial radiograph of the heel.

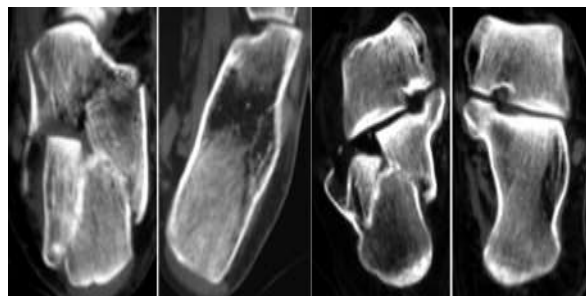


Fig. (5) Coronal (A) and transverse (B) computed tomographic scans.

When a patient's wrinkle test result was 6, only then would they be accepted for surgery (skin over the lateral aspect of the calcaneus should wrinkle and be free of pitting edoema with ankle dorsiflexion and foot eversion). The average amount of time it took for a positive wrinkle test to appear after a traumatic event was 9 days.

**Surgical technique**

A tourniquet was applied, and the patient was placed on their side so that the fracture could be seen from both the side and the top during surgery. It involves inserting a 5 mm Schanz screw into the posterolateral tuberosity of the calcaneum. To achieve a closed decrease of the tuberosity, moderate physical distraction and varus-valgus levering are used. Then, an incision four to five centimetres long is made in a straight line toward the base of the fourth metatarsal, beginning at the tip of the lateral malleolus and ending at the level of the calcaneocuboid joint. Following debridement, the injured posterolateral fragment is raised and everted while its soft-tissue attachments are maintained. Between the posteromedial sustentacular fragment and the tuberosity, this provides access to release the affected medial wall. The tuberosity is then levered medially and placed in a little over decreased position behind the sustentacular fragment when the distraction is removed. After using a K wire to steady

the reduction momentarily, the intensifier was used to make sure everything was in working order. Four millimetre cannulated screws were used to decrease and stabilise the anterior facet, and a curved periosteal elevator was inserted into the sinus tarsi to accomplish a reduction of the medial wall. Two 4 mm cannulated screws were inserted laterally to medially through the talus to decrease the sustentaculum tali. The procedure culminated in the insertion of cannulated screws through the posterior tuberosity and into the calcaneocuboid joint through percutaneous means. Re-approximating the split fascia and interval, and maybe running sutures to the skin over a suction drain, are used to seal the incision. 12

The patient wears a compression bandage for two weeks, during which time they are encouraged to move their ankle and subtalar joint very slowly and gently. In doing so, any imperfections in the articular surface are shaped to perfection. In this case, the patient must not bear any weight. After two weeks, the sutures are taken out and a cast is placed below the knee. Once the cast has been on for six weeks, it is time for follow-up X-rays. The patient is to begin range of motion exercises, but weight bearing is still not to begin at this time. Eight to twelve weeks after surgery, the patient may begin weight bearing.

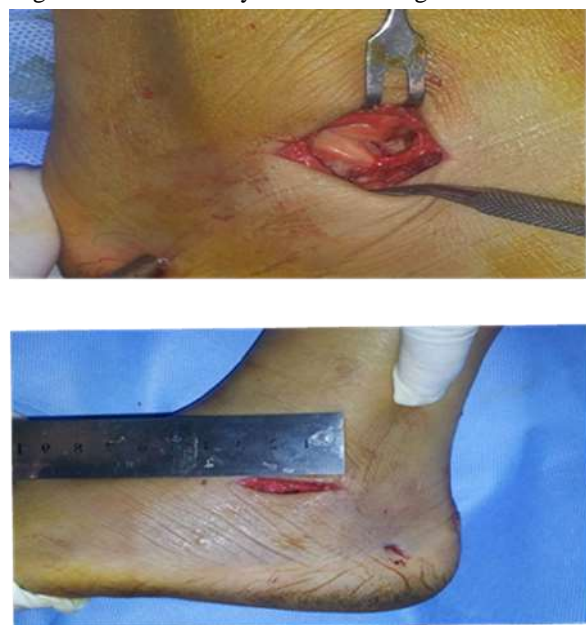
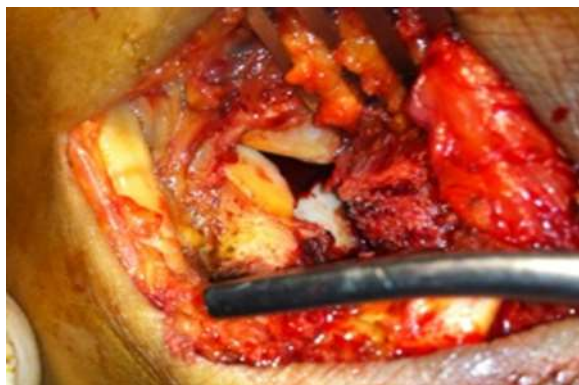
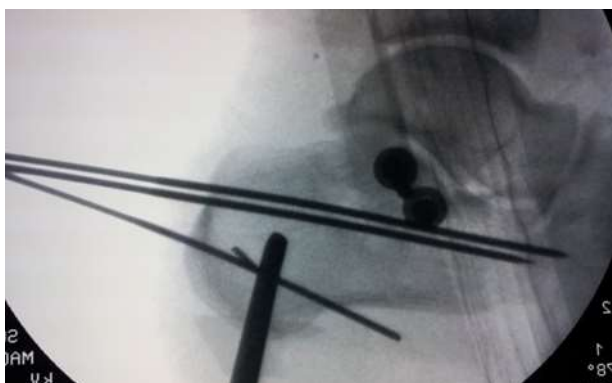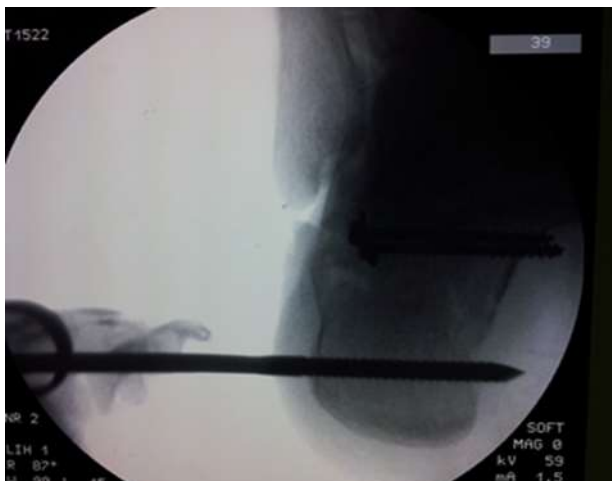Fig. (6) a,b Intra-operative photo showing the incision.



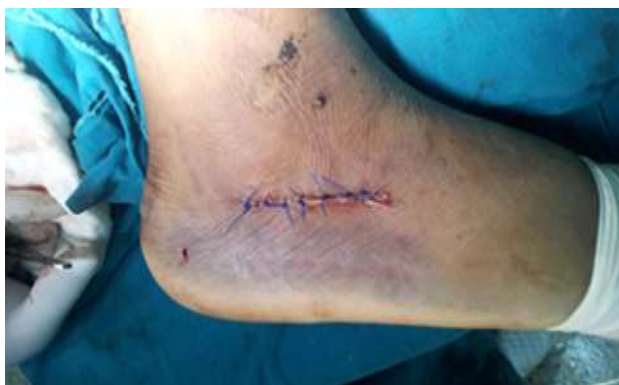**Fig. (7)** Intra-operative photo showing posterolateral and blowout fragments



**Fig. (8)** intra-operative fluoroscopic photo after posterolateral fragment fixation



**Fig. (9)** reduction of tuberosity fragment using schanz screw



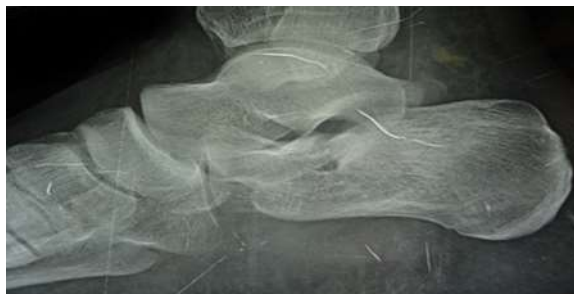**Fig. (10)** Intra-operative photo showing the wound after closure.

**All the patients were assessed clinically and radiologically.**

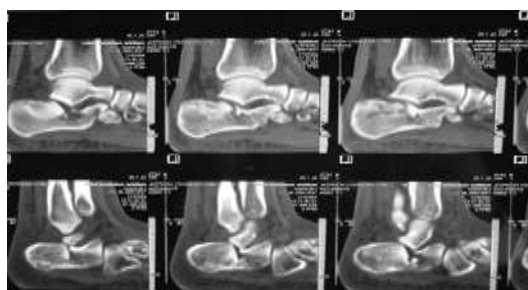
Patients underwent a clinical examination by either (a) the American Orthopaedic Foot and Ankle Society (AOFAS) or (b) a combination of both organisations. There is a maximum score of 100 possible. It's a medical rating scale. Clinical outcomes were ranked as 90–100 outstanding, 80–90 good, 70–80 fair, or less than 70 bad. The 13 (b) Maryland results are as follows: You've earned a perfect score of 100. This number is used in the medical field. Scoring between 90 and 100 is outstanding;

between 75 and 89 is acceptable; between 50 and 75 is decent; and below 50 is bad.

All patients had a full radiological evaluation after surgery and during their follow-ups. This evaluation comprised anteroposterior, lateral, and Harris axial views. All patients had X-rays taken at six weeks, twelve weeks (when weight bearing begins), six months, and one year. The occurrence of joint or calcaneal body displacement of 2 mm was considered loss of reduction. Bohler's angle, Gissane's angle, and calcaneal height were all measured in the lateral view of the ankle, whereas calcaneal breadth was measured in the axial view.



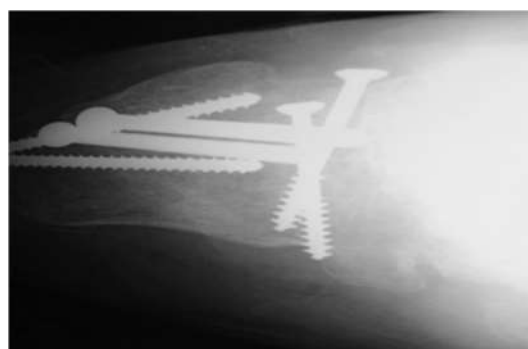**Fig. (11)** x ray showing lateral view of the calcaneus.



**Fig. (12)** CT showing sagittal cuts of the calcaneus.



**Fig. (13)** postoperative lateral view and axial view of the calcaneus



**Fig. (14)** postoperative lateral view and axial view of the calcaneus

### 3. Results

There were a total of 30 displaced intraarticular calcaneal fractures in 27 individuals. Of them, 24 were unilateral and 3 were bilateral. There were 23 male patients and 4 female patients. The mechanism of injury in 20 of the fractures (66.6%) was a fall from a height, and in 10 of the fractures, the cause of damage was a car collision. Based on CT scan results, we classified all fractures using Sander's system, and found that 19 of them were type 2 and 11 were type 3. Ranged from 6 months to 24 months, with an average of 13.3 months of follow up. From two to twenty-one days, the average period between injury and surgery was 9.93 days.

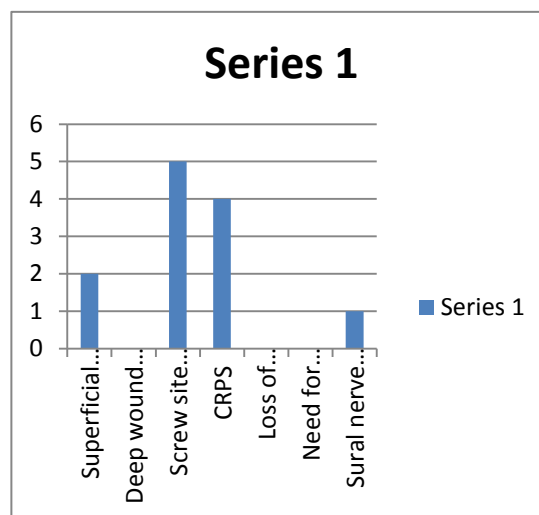
Without any serious complications, every broken bone healed. Seventeen patients reported discomfort in their feet after surgery, most noticeably at the subtalar joint and at the place where screws had been implanted.

**Table (1)** showing the scores of the patients according to AOFAS ankle/hindfoot score.

	Frequency	Percentage %
<b>Excellent (90-100)</b>	21	70
<b>Good (80-90)</b>	6	20
<b>Fair (70-80)</b>	2	6.6
<b>Poor (less than 70)</b>	1	3.3

**Table (2)** showing scores according to Maryland foot score.

	Frequency	Percentage %
<b>Excellent (90-100)</b>	26	86.6
<b>Good (75-89)</b>	3	10
<b>Fair (50-75)</b>	1	3.3
<b>Poor (less than 50)</b>	0	0



**Chart (1)** complications

### 4. Discussion

There is limited hope for recovery from a displaced intra-articular fracture if non-operative therapy is pursued. This is because non-operative treatment often leads to calcaneal malunion, heel shortening and widening, and peroneal tendon impingement via the lateral wall. [9]

It was discovered that the AOFAS ankle/hind foot score and the Maryland foot score are significantly correlated with the time elapsed between the trauma and the procedure. This is likely due to how hard it is to fix the cracks after the material has begun to solidify. It is clear from this that calcaneus fractures with disruption of

the intra-articular space should be treated as soon as feasible with open reduction and internal fixation. Therefore, it's crucial to take steps to reduce edoema after a fracture, such as elevating the affected area and using anti-edematous drugs.

The prolonged lateral L-type method with lateral plate fixation is favoured by several writers. Nonetheless, there is a chance that the skin won't recover properly because of how comprehensive this method is. It makes the central and anterior devascularization of the lateral wall worse after trauma.



Wound-related complications account for the majority (33%) of all reported general complications.

Infected: 14%; Approximately 32%

18% of people with a CRPS and 10% of those with a sural nerve damage.

As a result of this issue, many strategies and fixation techniques were devised. The Collaborators Weber et al.

Patients in this series had a lower risk of wound infection than those in a similar study that used a lateral technique (Howard et al., 2010).

17 Possible explanation: the incision in this investigation avoided cutting into a vein. In addition, Howard et al. claimed a mean delay of just 5–6 days for the procedure, but the actual mean delay was 8.23 days. 15 When compared to the other trials, ours shows a much lower incidence of wound-related consequences such as delayed healing, infection, and nerve injury. The positive wrinkle test and careful surgical execution after the edoema has subsided likely had a role in this. Patients who have surgery during the first week following an accident have been shown in previous research to be at a higher risk of wound complications. 16 Contrary to what the mean suggests, displaced intra-articular calcaneus fractures may be successfully treated with open reduction and internal fixation. 26 Both total wound complications and infection occurred at a rate of 3% in this research. Incidences of both sural nerve damage (3%) and CRPS (21.2% ) were rather low. Each of these issues was handled cautiously.

Both the restricted subtalar technique and the more invasive extensile lateral approach were used on the patients. This novel method allowed for visual open reduction and internal fixation of the articular surface. The fracture's extra-articular extensions were minimised and repaired under fluoroscopic guidance. The notion of minimally invasive osteosynthesis (MIO) is leveraged here to decrease the risk of skin problems, which are otherwise common with the more traditional extensile lateral technique. Both groups were able to accomplish anatomical reduction, however the restricted reduction group saw less wound complications.

Weber et al. treated patients using an extensile lateral approach and restricted open reduction and internal fixation, and their outcomes were comparable to those found in this research. [12]

The average ankle and hind foot AOFAS score is greater than in the norm. This might be because the patient was allowed early range of motion within the first two weeks, but in the trial by Weber et al., the patient was placed in a short leg cast and had to remain weight-bearing for six weeks. [12]

One of the study's strengths is that all patients had the identical preoperative examination and surgical procedure. The identical procedure was used for both the post-op check-ins and the physical therapy.

The study's limitations come from the small sample size. It is possible that the findings might change if individuals with bilateral injuries and accompanying injuries were included in the analysis.

## 5. Conclusion

Screw fixation is an effective, safe, and repeatable minimally invasive technique for treating sanders type II and III calcaneal fractures with a restricted lateral subtalar approach.

To mend a calcaneal fracture with this approach is to do so with much less trauma to the bone. The fracture may be seen clearly, and the articular surfaces can be reduced to their anatomical shapes.

## References

- [1] DM.Eastwood, VG.Langkamer, RM.Atkins, Intra-articular Fractures of the Calcaneum. Part II: Open Reduction and Internal Fixation by the Extended Lateral Transcalcaneal Approach. *J Bone Joint Surg Br*,vol.75(2),pp. 189-95,1993.
- [2] PB.Magnuson, An operation for relief of disability in old fractures of os calcis. *Journal of the American Medical Association*,vol.80(21),pp.1511,1923.
- [3] T.Schepers, EM.van Lieshout, AZ.Ginai, PG. Mulder, MJ.Heetveld, P Patka, Calcaneal fracture classification: a comparative study. *J Foot Ankle Surg* vol.48,pp.156-62,2009.
- [4] P.Essex-Lopresti The mechanism, reduction technique, and results in fractures of the os calcis. *Br J Surg* 1952;39:395-419.Quoted from Tomesen T, Biert J, Frolke JP Treatment of displaced intra-articular calcaneal fractures with closed reduction and percutaneous screw fixation. *J Bone Joint Surg Am*,vol.93,pp.920-8,2011.
- [5] A.Greenspan Orthopedic Imaging: A Practical Approach. In: 4th Edition ed: Lippincott Williams & Wilkins, ,vol.334,pp.45-25,2004.
- [6] R.Sanders, P.Fortin, T.DiPasquale, A.Walling, Operative treatment in 120 displaced intraarticular calcaneal fractures. Results using a prognostic computed tomography scan classification. *Clin Orthop Relat Res*,vol.784,pp.87-95,1993.
- [7] RW.Sanders, MP.Clare, Rockwood & Green's Fractures in Adults,Fractures of the Calcaneus, 6th Edition ed. Philadelphia, Lippincott Williams & Wilkins ,vol.411,pp.2294-334,2006.
- [8] JA.Albright, The scientific basis of orthopaedics. In: Brand RA, ed., 2nd ed. California: Appleton and Lange, 1987:213-39.Quoted from Athavale SA, Joshi SD, Joshi SS Internal architecture of calcaneus: correlations with mechanics and pathoanatomy of calcaneal fractures. *Surg Radiol Anat*,vol.32,pp.115-22,2010.
- [9] R.Sanders, Displaced intra-articular fractures of the calcaneus. *J Bone Joint Surg Am*,vol.82,pp.225-50,2000.
- [10] SK.Sarrafian, Anatomy of the Foot and Ankle: Descriptive, Topographic, Functional. Philadelphia: Lippincott, 1983. Sanders R Displaced intra-articular fractures of the calcaneus. *J Bone Joint Surg Am*,vol.82,pp.225-50,2000.
- [11] M.DeWall, CE.Henderson, TO.McKinley, T .Phelps, L.Dolan, JL.Marsh, Percutaneous reduction and fixation of displaced intraarticular calcaneus

- fractures. *Journal of orthopaedic trauma*, vol.24(8),pp.466,2010.
- [12] M.Weber, O.Lehmann, D.Sagesser, F.Krause.. Limited open reduction and internal fixation of displaced intra-articular fractures of the calcaneum. *J Bone Joint Surg Br*, vol.90, pp.1608-16,2008.
- [13] HB.Kitaoka AIAR, JA.Nunley, M.Myerson, M.Sanders, Clinical rating systems for the anklehindfoot, midfoot, hallux and lesser toes. *Foot Ankle Int*, vol.15, pp.349-53,1994.
- [14] SK.Benirschke, BJ.Sangeorzan, Extensive intraarticular fractures of the foot. Surgical management of calcaneal fractures. *Clin Orthop Relat Res*, vol.292, pp.128-34,1993.
- [15] JL. Howard, R.Buckley, R.McCormack, G.Pate, R.Leighton, D.Petrie, R.Galpin, Complications following management of displaced intra-articular calcaneal fractures: a prospective randomized trial comparing open reduction internal fixation with nonoperative management. *J Orthop Trauma*, vol.17, pp.241-9,2003.
- [16] M.Al-Mudhaffar, CV.Prasad, Mofidi A Wound complications following operative fixation of calcaneal fractures. *Injury*, vol.31, pp.461-42000.
- [17] RW.Sanders, MP.Clare, Fractures of the calcaneus in the *Surgery of the Foot and Ankle*, Coughlin MJ, Mann RA, Saltzman CL. (eds), Mosby Elsevier 8th ed, vol.45, pp.2017-2073,2007.
- [18] JG.Kennedy, WM.Jan, AJ.McGuinness, K. Barry, J.Curtin, WF.Cashman, GB.Mullan, An outcomes assessment of intra-articular calcaneal fractures, using patient and physician's assessment profiles. *Injury*, vol.34, pp.932-6,2003.